1

History of Hernia

Chapter Outline

- Open Anterior Hernia Repair
- Open Preperitoneal Posterior Approach
- Laparoscopic Approaches
- Synthetic Material
- Ventral Hernia
- History of Hiatal Hernia Surgery
- Hiatal Hernia before the 20th Century
- Hiatal Hernia in the First Half of the 20th Century
- Hiatal Hernia in the Second Half of the 20th Century

No disease of the human body, belonging to the province of the surgeon, requires in its treatment, a better combination of accurate, anatomical knowledge with surgical skill than hernia in all its varieties.
Sir Astley Paston Cooper, the Anatomy and Surgical Treatment of Inguinal and Congenital Hernia, Cox, London, 1804

A *hernia* is a protrusion of visceral contents through the abdominal wall. There are two key components of a hernia. The first is the defect itself, namely the size and location of the defect. The second component is the hernia sac, which is a protrusion of peritoneum through the defect. The hernia sac may contain abdominal contents such as omentum, small intestine, colon or bladder, or the sac may be empty.

The advantage of the human being to walk erect, undoubtedly led to cases of vulnerability between the abdominal muscle wall (ability for the expansion) and the hard pelvic bones. In addition, the passage of various structures of the trunk to the extremities (femoral nerve, iliac artery and vein, the spermatic cord) through the distal ends of the abdominal muscles, at their insertion upon the pubic bone. For these reasons, an adult inguinal hernia, which in part resulted from weakness of the inner envelope of the abdominal wall (transversalis fascia), is one of the most common known ailments since ancient times.

Groin hernias originate in the abdomen and traverse a myopectineal orifice between abdomen and thigh to present in the inguinal region (Fig. 1.1). The myopectineal opening, as described by Fruchaud (Fig. 1.2), is bounded by the rectus sheath medially, internal oblique and transversus abdominis muscles superiorly, the iliopsoas muscle laterally and pubis inferiorly. It is an irrefutable anatomic structure whose entire opening must be addressed before a complete cure of inguinal-femoral hernia can be anticipated.

The human imagination had emerged of hundreds of procedures and methods, some quite morbid, of managing inguinal hernias. These varied from conservative, nonoperative management (taxis) to less painful binding devices, to hot irons applied to the groin to cause scarring.

TAXIS from its Greek origin, meaning the drawing up in rank and file, involved the use of finger or hand pressure to reduce the displaced organ or tissue. Support after reduction, utilizing a belt or girdle to maintain the herniated content, would have been a logical extension of taxis (Figs 1.3A and B).

Surgical intervention was used only as a last resort, usually when the patient was critically ill, and the date of the first operation for hernia and change in the nonoperative management is unknown.

However, allusion to an operative procedure for hernia was made in one of the earliest written medical records,

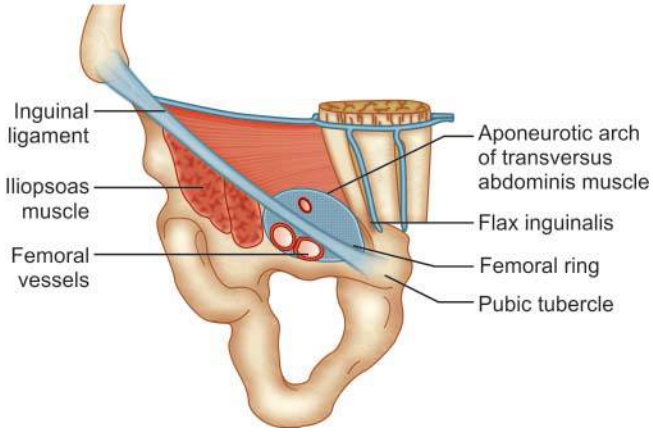

Fig. 1.1: The myopectineal orifice. Superior to the inguinal ligament, this area includes the inguinal (Hesselbach's) triangle. Inferior to the ligament, the orifice transmits the iliopsoas muscle, the femoral nerve and vessels, and the femoral canal and sheath

Fig. 1.2: Henri Fruchaud

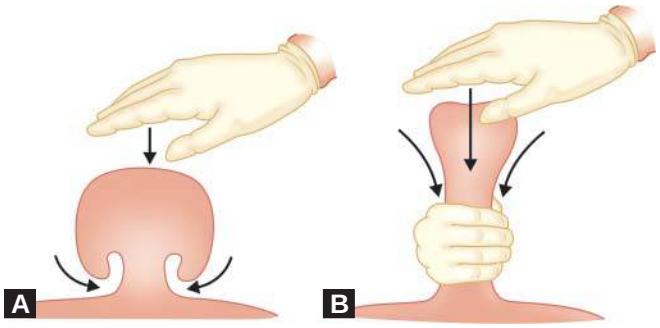

Figs 1.3A and B: Reduction of a hernia by taxis: (A) Applying pressure on the hernia directly occludes the neck; (B) Elongating the neck of the hernia while applying pressure allows reduction

an ancient Egyptian medical text known as the Ebers Papyrus (Fig. 1.4).

German novelist and Egyptologist Georg Moritz Ebers (1837–1898), a professor of Egyptology at the University of Berlin (Fig. 1.5), purchased an ancient papyrus while traveling in Egypt in 1873. The papyrus contained a collection of older works dating back to 3,000–2,500 BC. Ebers prepared a partial translation of the papyrus in 1875, which was later completed by Bendix Ebbell, a Norwegian physician. Ebbell's study of the papyrus suggested that the ancient Egyptians had attained a high level of surgical skill and had developed procedures for hernia and aneurysm management.

Fig. 1.4: Ebers medical papyrus

Fig. 1.5: Georg Moritz Ebers

Georg Moritz Ebers is famous for discovering one of the most important Egyptian medical papyri in the world. His scholarly interests also led him to create historically accurate romance novels that celebrate Egyptian lore, like Serapsis (1885) and Kleopatra (1894).

The discovery of anesthesia and the development of antiseptic methods in the mid-19th century revolutionized the practice of surgery.

Development of anesthesia techniques in the 1860s allowed more invasive methods to be used in the treatment of non complicated inguinal hernias.

OPEN ANTERIOR HERNIA REPAIR

In the late 19th century, Tait advocated primary surgical management of groin hernias that he used a transabdominal approach to suture the defect. This approach fell from favor when Eduardo Bassini in 1887, introduced the first true anatomical repair.

Henry O Marcy (1837 1924), a surgeon from the USA and a disciple of the English surgeon Joseph Lister, described two cases of incarcerated hernia that he treated surgically in 1871. Marcy, using Listerian antiseptic techniques, performed the standard operation of the day on these two patients: he divided the hernia ring in the usual way with the hernial knife and reduced the incarcerated hernia. However, Marcy went a step further and expanded the hernia technique then in vogue. Rather than open the hernia sac, he reduced it and repaired the defect by closing the constricting ring with carbolized catgut suture.

Marcy, in his report of these procedures, emphasized the use of Lister s antiseptic technique and a new form of sterile (carbolized catgut) suture. He stressed that the two patients healed without infection. Almost as an afterthought, he noted that both patients were cured of their hernias. In truth, Marcy may have been the first to have closed the internal ring for hernia repair and probably helped to initiate the modern age of hernia repair.

Although Marcy made significant contributions to herniology, it is generally agreed that the Italian surgeon Eduardo Bassini (1844 1924) is the progenitor of modern hernia repair (Fig. 1.6).

Eduardo Bassini revolutionized the treatment of inguinal hernias by the introduction of a technique designed to restore the area of the hernial orifice.

Bassini, in 1884, devised a method of hernia repair that called for a three-layer reconstruction of the inguinal floor. After division of the posterior wall of the inguinal canal and herniotomy (high ligation and excision of the sac), Bassini performed a triple layer repair of the inguinal floor. He approximated the internal oblique muscle, transversus abdominis muscle and transversalis fascia to the inguinal ligament.



Fig. 1.6: Eduardo Bassini

According to Bassini, this herniorrhaphy technique (suture reinforcement of the floor of the inguinal canal) repaired the inguinal defect(s), re-established the obliquity of the inguinal canal, and reconstructed the internal and external inguinal rings, restoring all to competency.

Bassini procedure was of great concern for surgeons in Europe and all over the world, during the last 100 years. Over a century and even today, surgeons continue to manage hernias based on several procedures all are depend mainly on the principle of approximating the muscles of anterior wall of the inguinal canal, reinforcement of the elements of the posterior wall of the inguinal canal and narrowing the internal (deep) hernial ring.

Unfortunately, the sound procedure that Bassini devised became corrupted during its dissemination worldwide. Surgeons, particularly in the USA, failed to appreciate the importance of dividing the transversalis fascia to expose all layers, and a true triple layer repair was often not accomplished.

Bassini initially reported a recurrence rate of about 3%. In the USA, experience with the Bassini repair, which was frequently modified and simplified by not dividing the transversalis fascia, differed from the Italian master, and recurrence rates ranged from 5% to 10% in most hands.

Because of the increased rate of recurrence after the Bassini procedure, the American and the European surgeons are made turn to other surgical procedures that are more responsive to the requirements of reducing the

rate of postoperative recurrences. In addition, an increased confidence of modern synthetic materials for making the hernia surgery heading toward tension-free hernia surgery, which are built primarily on the use of prosthetic mesh.

Modifications have been added by many famous surgeons, such as Halsted, Marcy, McVay and Shouldice, resulting in excellent results at specialized hernia centers.

In 1945, Shouldice described a modification of Bassini's technique in which the inguinal floor was divided and then reconstructed in four layers. This technique, could be performed under local anesthesia, was widely adopted because recurrence rates were decreased dramatically.

The drawback of the Bassini technique and its modifications is that the repair pulls adjacent tissues together in nonanatomic opposition, resulting in increased tension, postoperative discomfort and increased risk of failure.

OPEN PREPERITONEAL POSTERIOR APPROACH

The preperitoneal space is situated between the transversalis fascia and the peritoneum. The transversus abdominis muscle and its aponeurosis and fascial coverings are probably the most important layer in the groin. The aim of hernia repairs should be to return this layer to normal. By strengthening the preperitoneal area, this goal can be achieved.

The preperitoneal or posterior approach for the repair of groin hernias is particularly useful with very large or recurrent hernias. Laparoscopic hernioplasty is an extension of the preperitoneal concept. In many of the laparoscopic repairs, the prosthesis is placed in the preperitoneal space.

Although Annandale, in 1876, was the first to enter the preperitoneal space for hernia repair, Cheatle, in 1920, is generally credited with being the first to introduce a preperitoneal (otherwise known as pro-peritoneal, extraperitoneal or posterior) approach. Cheatle described his procedure as follows: an incision is made to one side of the middle line, the rectus abdominis is split longitudinally and the abdominal wall is retracted to the side of the operation. The hernia sac was ligated as low down as possible and the internal ring closed by suturing the muscle fibers and their sheath.

Nyhus and colleagues later adopted and further refined the open preperitoneal repair. They recommended that the preperitoneum be approached via a suprainguinal incision and that suture plasty (herniorrhaphy) be performed to secure the defects of indirect, sliding and recurrent inguinal hernias.

In 1989, Lichtenstein introduced the tension free repair which involved reconstruction of the floor of the inguinal canal using a synthetic mesh with the intention of reducing the recurrence rate. This technique was regarded as being easier to learn and resulted in a reduction in operations for recurrence not only in specialized centers but also in national registers. This has become the most widely employed technique today.

In the 1986 edition of his textbook Hernia Repair Without Disability, Irving L Lichtenstein stated that he was performing a tension free repair utilizing synthetic mesh to bridge the hernia defect and that he had discarded older classical techniques of suture repair (herniorrhaphy). Tension, as noted by Lichtenstein, could lead to suture or tissue disruption and hernia recurrence. He reported that tension-free repair with mesh prosthesis had been employed in more than 300 consecutive cases of direct and indirect inguinal hernia without complication or recurrence.

In 1980s, Stoppa and Nyhus used the preperitoneal approach by bridging the hernia defects with prosthetic mesh.

Ren Stoppa and colleagues performed much of the innovative work that ultimately formed the foundation for a successful laparoscopic approach to hernia repair. Stoppa's contribution to herniology was that he suggested managing hernias of the groin with a very large, permanent prosthesis that would functionally replace the transversalis fascia. Stoppa advocated an extensive reinforcement of transversalis fascia without repair of the hernia defect.

Whereas the goal of surgical therapy had always been to achieve parietal repair, i.e. closure of the hernia defect, Stoppa's revolutionary concept was to render the peritoneal envelope inextensible without mandatory repair of the deteriorated abdominal wall and hernia defect. The operation has become known as the giant prosthetic reinforcement of the visceral sac *(GPRVS)* or Stoppa procedure, and has worked quite well with low recurrence rates reported for even very large, complex, recurrent hernias.

Most of these procedures were characterized by something in common: it's speedy, ease of performance and relative safety, compared with other interventions on the abdomen. For this reason, Hernia surgery has become (in the late 20th century), an effective procedure, and bear less recurrence rate, in addition to its ease of performance and its safety to the patient.

Any surgical procedures to be followed for the accurate curative for inguinal hernia should include the following essential primary and secondary points.

Primary Points

- Repair of the hernia and/or the hernial defect.
- Reduce the incidence of recurrence or rather completely cancel it.

Secondary Points

- Reduce the trauma of the surgical maneuvers to the anatomical structures at the hernial defect, as possible.
- Good management of postoperative pain as possible so that the patient is well tolerated of the procedure.
- Make the process more easy and efficient.
- Make the cost of the procedure within an acceptable range to perform a cost-effective laparoscopic hernioplasty and discharge the patient as rapidly as possible.
- Rapid recovery with a short convalesce period and return to normal activity and work as quickly as possible.

Successful laparoscopic hernia repair should achieve the above objectives by less traumatic and minimal invasive approaches to the tissues.

LAPAROSCOPIC APPROACHES

Since its introduction by Ger in 1982 into the armamentarium of hernia repairs, laparoscopic repairs have undergone considerable evolution and have been the source of much controversy.

With the appearing of the era of laparoscopic surgery, some surgeons had been suggested to apply this new technology (prosthetic material) on the laparoscopic hernias surgery because it (the laparoscopic surgery) fulfils all the primary and secondary points for the perfect hernia surgery.

The most important point provided by laparoscopic surgery that it dealt with the hernia at the point of its origin exactly within the abdominal cavity at the level of the groin holes, and not at the inguinal canal, where the hernial sac follows its way.

The technique of laparoscopic inguinal hernia repair was developed in the early 1990s and builds on the methods originally championed by Ren Stoppa *(open preperitoneal approaches).*

Ger in 1982 attempted minimal access groin hernia repair by closing the opening of an indirect inguinal hernial sac using Michel clips.

In 1989, Bogojavlensky reported filling an indirect hernia defect with a plug of polypropylene mesh followed by laparoscopic suture closure of the internal ring.

In 1990, Phillips and McKenna developed totally extraperitoneal (TEP) technique with or without peritoneoscopy.

In 1991, Arregui described the transabdominal preperitoneal (TAPP) approach with full exposure of the inguinal floor and placement of a large preperitoneal prosthesis.

Toy and Smoot in 1991 described a technique of intraperitoneal onlay mesh (IPOM) placement, where an intra-abdominal piece of polypropylene or e-polytetrafluoroethylene (ePTFE) was stapled over the myopectineal orifice without dissection of the peritoneum.

It was not until the 1990s with the tremendous success of laparoscopic cholecystectomies that the laparoscopic hernia repair received much attention. Early reports used a wide variety of techniques, initially met with high recurrence rates and numerous complications.

The present day techniques of laparoscopic hernia repair evolved from Stoppa s concept of preperitoneal reinforcement of fascia transversalis over the myopectineal orifice with its multiple openings by a prosthetic mesh. In the early 1990s, Arregui and Doin described TAPP repair, where the abdominal cavity is first entered; peritoneum over the posterior wall of the inguinal canal is incised to enter into the avascular preperitoneal plane which is adequately dissected to place a large (15 10 cm) mesh over the hernial orifices. After fixation of the mesh, the peritoneum is carefully sutured or stapled. Transabdominal Preperitoneal approach has the advantage of identifying missed additional direct or femoral hernia during the first operation itself.

Around the same time Phillips and McKernan described TEP technique of endoscopic hernioplasty where the peritoneal cavity is not breached and the entire dissection is performed bluntly in the extraperitoneal space with a balloon device or the tip of the laparoscope itself. An advanced knowledge of the posterior anatomy of the inguinal region is imperative. Once the dissection is complete, a 15 10 cm mesh is stapled in place over the myopectineal orifice. It appears to be the most common endoscopic repair today.

In both these repairs, the mesh in direct contact with the fascia of the transversalis muscle in the preperitoneal space, allows tissue ingrowths leading to the fixation of the mesh (as opposed to being in contact to the peritoneum as in IPOM repair where it is prone to migrate).

The two techniques (TAPP and TEP) proved more effective and emerged as the most popular.

These repairs approach the myopectineal orifice posteriorly, similar in anatomical perspective to the open preperitoneal approaches. A clear understanding of the anatomy from this perspective is crucial to avoid a number of complications, mainly vascular and nerve injuries.

Laparoscopy provides a clear view of the entire myopectineal orifice, and repairs of both inguinal and femoral hernias can be performed.

Initially, the dissection of the extraperitoneal space in the TEP approach tended to be difficult, confusing, and therefore hard to learn. With the advent of balloon dissectors, this exposure became simpler.

Complications related to the TAPP technique were almost completely eliminated by the TEP approach, operative times were reduced, and recurrence rates remained low. Simultaneous with the increased popularity of the TEP approach; however, some modifications in the TAPP approach that have made outcomes with both approaches comparable. Current thinking is that both approaches are acceptable with special circumstances when one laparoscopic technique is preferred over the other, or where even an open anterior repair will better serve the patient.

Initially, the majority of surgeons were limited to a single laparoscopic approach, TAPP approach, which became the standard for laparoscopic hernia repair and many studies were published demonstrating recurrence rates of less than 1%. When complications such as internal hernias from inadequate closure of the peritoneum and injury to viscera from trocars and needles placed in the peritoneal cavity were reported, a totally TEP approach was developed and subsequently adopted by many laparoscopic surgeons. This approach required the surgeon to laparoscopically expose the extraperitoneal space without entering the peritoneal cavity. Although the TAPP approach had a history of success, the TEP approach potentially offered several advantages and slowly gained popularity. The approach had the potential to eliminate complications related to violating the peritoneal cavity and to reduce operative times, especially for bilateral hernia repairs.

The third technique of laparoscopic hernia repair includes the ways which access the abdominal cavity also through the peritoneum (intra-abdominal approach), and places a large piece of mesh against the peritoneum. The mesh is secured with staples placed into the same anatomic structures as in the TAPP repair but is placed in an intraperitoneal position instead of a preperitoneal position, i.e. it is in direct contact with the intestinal loops: *IPOM.*

The basic principle of all laparoscopic surgical procedures should be (tension free), i.e. the use of prosthetic synthetic material.

Despite the controversy concerning laparoscopic versus open hernial repair, most surgeons accept the laparoscopic inguinal herniorrhaphy as it has a clear advantages. Laparoscopic repair of an inguinal hernia (unilateral, bilateral and recurrent) results in less postoperative pain with the decreased need for postoperative analgesia, shorter hospital stay and an earlier return to normal activities. Additionally, repair of recurrent hernias is facilitated by access to the unscarred, undistorted clear preperitoneal space in the laparoscopic repair. To those ends, all contemporary general surgeons should be comfortable with the laparoscopic approach to inguinal herniorrhaphy.

The choice of laparoscopic approach depends on the surgeon's level of experience, the type of hernia present and the patient's history.

Depending upon the level of laparoscopic expertise of the surgeon and its ability, it became apparent, however, that success with laparoscopic approach is patient selection that the surgeon's decision to apply proper techniques to appropriate patients .

SYNTHETIC MATERIAL

The earliest use of synthetic material to substitute for living tissues in herniorrhaphy occurred in 1894 and involved the use of silver wire coils placed in the inguinal canal to induce fibrosis and strengthen the hernia repair. A few years later, German surgeons Goepel and Witzel independently utilized handmade silver wire filigrees to serve as a prosthetic mesh for difficult or recurrent hernias. Silver wire, however, lacked pliability and caused patient discomfort. It was not inert, and metal fatigue led to disintegration of the silver wires. Infection and sinus tract formation with persistent drainage occurred, and silver wire was eventually abandoned as prosthesis for hernia repairs.

Despite a genuine need for fascial substitutes, investigation of prosthetics for hernia repair was unfocused until the seminal work of Francis Usher (1908 1980).

Usher, in the 1950s, became interested in hernia recurrence and attempted to repair hernias with freeze-dried homographs and lyophilized dura mater. None of these materials proved satisfactory, so Usher turned his attention to synthetic materials. Various forms of plastic had been tried before, but because of their rigidity, tendency to fragment and susceptibility to infection, none was found to be satisfactory for hernia repair. Usher persisted in his investigation of plastic materials and learned of a new polyolefin plastic (polypropylene, i.e. Marlex) that could be extruded as a monofilament, did not fragment, and was inert. Usher worked closely with the company that produced Marlex (Phillips Petroleum Co.), and had the material woven into a mesh and tested in animal studies. He found that polypropylene mesh was tolerated well in sterile and infected fields, and he began to use Marlex mesh in humans in 1958.

VENTRAL HERNIA

A hernia is defined as the protrusion of viscera from the abdominal cavity through a natural, preformed, anatomical

route, while an incisional hernia indicates the protrusion of viscera from the abdominal cavity through a route formed after trauma induced by cutting (surgical incision, laparoascopic trocar puncture wounds and stab wounds).

Ventral hernia refer to facial defects of the anterolateral abdominal wall through which intermittent or continuous protrusion of preperitoneal fat, intestinal contents, or rarely, an abdominal organ may occur, they are either congenital or acquired.

In adults, more than 80% of ventral hernias result from previous surgery hence the term *incisional hernias*. They have been reported to occur after 0 26% of abdominal procedure. Although these hernias mostly become clinically manifest between 2 years and 5 years after surgery, studies have shown that, *the process starts within the first postoperative month.* They are said to occur as a result of a biomechanical failure of the acute fiscal wound coupled with clinically relevant impediments to acute tissue repair and normal support function of the abdominal wall.

Historically, incisional hernias have repaired with either primary suture techniques or placement of a variety of prosthetic materials.

Even though numerous case studies of surgically treated incisional hernia were published early on, the history of specific surgical treatment of incisional hernia began in the second half of the 1800s. Before that, surgeons used exclusively restraining methods . Surgical treatment or, to use the less elegant term coined by several authors, bloody treatment, developed along three lines: (1) Simple laparoplasty, (2) Organic auto or heteroplasty and (3) Alloplasty.

Simple laparoplasties were carried out according to Gosselin s anatomopathological and clinical descriptions. In the beginning, suturing of the wall-defect breach was carried out transcutaneously on a closed abdomen.

Successively, between 1880 and 1900, aponeurotic suturing techniques on one or more planes, with or without opening of the peritoneum, were introduced and increased in number.

In 1896, Quenu described the suturing of several layers adjacent to the incision of the rectus muscle sheath and along its medial margin, suturing of the posterior face of the sheath of one rectus muscle with the posterior face of the contralateral one, and suturing of the muscle edges preceded by suturing of the anterior face of the two rectus muscles. This technique was particularly recommended in cases of diastasis of the rectus abdominis muscles. In reality, this method represented an autoplasty through the use of the lamina anterior and posterior musculi recti abdominis.

During the next stage in the evolution of a surgical approach to treating incisional hernia, plasty was proposed using U shaped muscle aponeurosis suture stitches or 8 shaped stitches through the entire thickness. These and other techniques were advocated with the aim of obtaining abdominal-wall reconstructions that would radically and definitively eliminate the pathology of incisional hernia. Some authors focused their efforts on incisional hernias situated in specific areas. Schulten , for example, dedicated his research efforts to umbilical-pubic incisional hernias.

Before the 1960s most ventral hernias were repaired primarily with suture and a few with metallic meshes. Even with some modification, recurrence rates with the primary suture repaired ranged from 24% to 54%. The introduction of polypropylene mesh repair by Usher in 1958 opened a new era of tension-free herniorrhaphy. Recurrence rates with prosthetic mesh decreased to 10 20%.

In recent times, due to the progress made in the chemical industries, numerous kinds of synthetic prostheses have rapidly appeared on the market and, while some of them have been short-lived, others have become progressively welle-stablished.

This succession has included nylon, dacron, teflon, ivalon, velourlined silicone and, above all, polytetrafluoroethylene (PTFE), the latter reducing the formation of adherences. Mersilene, introduced in France by Rives , is the material of choice for most French surgeons, while in the United States surgeons generally prefer marlex (polypropylene). The last three materials better respond to the needs of surgery in the repair of incisional hernias. This was stressed by Arnaud, who, in 1977, stated that a prosthesis must not be toxic, must last in time, must be flexible and resistant, must have the right strength and provoke minimal tissue reaction.

Subsequently, it was realized that the placement and fixation of the mesh was more crucial in determining the outcome of the repair. The placement of the mesh in the preperitoneal, retromuscular position with a wide overlap of least 5 cm over the hernia defect in all direction was introduced in the late 1980s. The refinement of this method decreased the recurrence rates to as low as 3 5% making it to be declared the standard of care of ventral hernias. However, implantation of the mesh by open techniques requires wide dissection of soft tissue contributing to an increase in wound infection and wound-related complications.

Laparoscopic access has also been proposed for repair of ventral incisional hernias. In 1993, LeBlanc and Booth described their experience with repair of incisional hernia using ePTFE prosthetic graft. Franklin and colleagues reported on the use of open-weave polypropylene mesh

for repair of ventral hernias. Notably, no fistula formation or significant adhesive bowel complications were found in their study. Kavic commented on the use of dual-mesh ePTFE (Gore-Tex) for abdominal-wall ventral hernia repair. Dual-mesh has a rough side and a smooth side. The smooth side of the ePTFE graft is intended to interface with intra-abdominal content and to not excite adhesion formation. The rough side is placed in apposition to the abdominal wall, where its rough surface encourages tissue adhesion. The graft is fixed circumferentially with staples or tacks and anchored with transfascial stay sutures placed at the four cardinal points of the graft. Carbajo and colleagues prospectively compared laparoscopic with open prosthetic repair of large incisional hernias. Their study suggested that laparoscopic repair reduces complication rates and hernia recurrence compared with open methods.

HISTORY OF HIATAL HERNIA SURGERY

The first report of hiatal hernia (HH) was published in 1853 by Bowditch. Rokitansky in 1855 demonstrated that esophagitis was due to gastroesophageal reflux, and Hirsch in 1900 diagnosed an HH using X-rays. Eppinger diagnosed an HH in a live patient, and Friedenwald and Feldman related the symptoms to the presence of an HH. In 1926, Akerlund proposed the term hiatus hernia and classified HH into the three types that we use today. The first elective surgical repair was reported in 1919 by Soresi. The physiologic link between HH and gastroesophageal reflux was made at the second half of the 20th century by Allison and Barrett. In the midst of a physiologic revolution, Nissen and Belsey developed their famous operations. In 1957, Collis published his innovative operation. Thal described his technique in 1965, and in 1967, Hill published his procedure. Many modifications of these procedures were published by Pearson and Henderson, Orringer and Sloan, Rossetti, Dor, and Toupet. Donahue and Demeester significantly improved Nissen's operation, and they were the first to truly understand its physiologic mechanism.

Hiatal hernia surgery has evolved from anatomic repair to physiological restoration.

Although congenital and post-traumatic diaphragmatic hernias were described as far back as the 16th century, hiatal hernia was not recognized as a significant clinical entity until the first half of the 20th century. Surprising as it seems to modern surgeons, the relationship between hiatal hernia and gastroesophageal reflux remained unnoticed until the 1950s. In the second half of the 20th century, an appreciation of the pathophysiology of gastroesophageal reflux changed hiatal hernia surgery from simple restoration of anatomy to more physiologic operations. At the dawn of the new millennium, technological advances in both diagnosis and therapy have made treatment of hiatal hernia and gastroesophageal reflux a major component of surgical practice. This review addresses the historical evolution of hiatal hernia repair and reports in a chronological fashion the major milestones in hiatal hernia surgery before the laparoscopic era.

HIATAL HERNIA BEFORE THE 20TH CENTURY

Ambrose Pare (1579), Rivierius Lazari (1689), Giovanni Batista Morgagni (1761), Vincent Alexander Bochdalek (1848) and many other distinguished physicians make up an impressive list of pioneers whose names have been associated with the first descriptions of post-traumatic and congenital diaphragmatic hernias. Acquired herniation through the esophageal hiatus (i.e. what is now referred to as hiatal hernia) had been described only in passing before the X-ray era. This is probably attributable to the classic autopsy techniques of the time in which the esophagus was usually cut just above the diaphragm and taken out with the heart and lungs, losing all connections with its intra-abdominal segment and stomach.

In 1819, Ren Th ophile Hyacinthe La' nnec described post-traumatic and congenital diaphragmatic hernias in his treatise on auscultation, De l auscultation mediate. He stated: it even appears that the stomach and intestines have at times been known to pass into the chest by the openings which afford a passage of the esophagus, aorta and even to the great sympathetic nerve. Sir Astley Cooper in 1824 also mentioned that protrusion of the viscera through the diaphragm could take place at the natural apertures formed for the passage of esophagus, vena cava, aorta or through unnatural openings. Cooper considered herniation the result of malformation or injury. In 1853, Henry Ingersoll Bowditch (Fig. 1.7) reviewed all cases of diaphragmatic hernia published between 1610 and 1846. The collected series of 88 cases, all postmortem findings, contained three cases of dilatation of the esophageal opening, which Bowditch characterized as very curious. In these three cases, Bowditch noted that esophagus presented a very abrupt change of its course. In all, it descended through the diaphragm as usual but turned back toward the left to enter the abnormal aperture caused by the hernia and to join the stomach in the chest. This was perhaps the first report of what is now classified as a type II or paraesophageal hernia.

While the recognition of hiatal hernia as a common anatomic abnormality would have to wait for the widespread adoption of X-rays, the damage done to the esophagus by gastroesophageal reflux was postulated in medical literature as early as 1800. Charles Michel Billard in Paris published the first case of esophagitis in a child in 1828. Carl Rokitansky, a pathologist in Vienna in 1855,

Fig. 1.7: Henry Ingersoll Bowditch reviewed the early series of hiatal hernias described at postmortem examination in 1846 and probably should be credited with the first description of what is now referred to as a paraesophageal hernia

demonstrated that esophagitis of the lower esophagus was due to gastroesophageal reflux. His report, however, had little impact on clinical medicine at that time. Many clinicians, such as Friedrich Albert von Zenker and Sir Morrel Mackenzie, felt reflux of gastric juice into the esophagus to be only an agonal occurrence with no clinical significance. When Heinrich Quincke in Germany attributed three cases of esophageal ulceration to the regurgitation of gastric juice in 1879, a heated controversy developed. This controversy persisted for over half a century. Wilder Tileston clearly described the typical symptoms of esophagitis in 1906. In his study, he reviewed 41 cases and he added 3 of his own. Although many of these patients had esophageal ulceration, as well as frequent vomiting and pyloric stenosis, the importance of his contribution lies in that Tileston gave a description of the typical symptomatology of esophagitis, and he felt that these symptoms were caused by insufficiency of the cardia. Joseph Sheehan described the esophagoscopic findings of esophagitis in 1920, and Porter Vinson was the first to note the association between esophagitis and stricture one year later. The term peptic esophagitis was introduced in 1934 by Hamperl on the basis of his pathologic studies almost 80 years after Rokitansky's work. One year later, Asher Winklestein introduced the term in the English literature.

HIATAL HERNIA IN THE FIRST HALF OF THE 20TH CENTURY

The advent of radiography was the first important step in the diagnosis and management of hiatal hernia. Around the turn of the century, a first-year medical student at Harvard Medical School (later to become a professor) named Walter Cannon begun a research project with a fellow second-year medical student, Albert Moser, studying deglutition with X-rays using bismuth capsules. The project had been suggested by the professor of physiology Henry Pickering Bowditch. They presented their work before the American Physiologic Society in 1898. Theirs was the first study of the anatomy and physiology of the cardia by means of contrast material. One year later, Moriz Benedikt repeated the experiments with a mercury-filled bougie, and in 1900, Hirsch diagnosed a hiatal hernia by means of X-rays and a mercury-filled balloon prior to autopsy. An increasing number of cases began to appear and at the turn of the century; it seemed like a new disease entity had emerged. Four years later, Eppinger diagnosed a hiatal hernia in a live patient. He made his diagnosis primarily on the basis of auscultation and then used X-rays to support his clinical judgment. In 1911, Eppinger summarized the literature of diaphragmatic hernia identifying 635 cases, of which only 11 cases involved the esophageal hiatus. In 1925, 33 cases were added by Carl Hedblom in an extensive review. In that same year, Julius Friedenwald and Maurice Feldman described the typical symptoms for the first time (i.e, heartburn) and related these to the presence of a hiatal hernia. They believed that the cause of the hernia was the failure of the muscle surrounding the diaphragm to closely encircle the esophagus. In 1926, Ake Akerlund in Stockholm reported 30 more cases, proposed the term hiatus hernia, and classified hiatal hernias into three types. Akerlund stated, "Diaphragmatic hernia through the esophageal hiatus may properly be termed hiatus hernia. They are most often true nontraumatic hernias and can be classified in three groups: (a) Hiatus hernias with congenitally shortened esophagus (thoracic stomach), (b) Paraesophageal hernias, (c) Hernias not included in (a) and (b)." He also noted that patients with hiatal hernia complained of pain immediately after ingestion of food, frequently associated with heartburn, and sometimes complained of dysphagia. Despite the prevailing opinion at the time, he concluded that hiatal hernia must be a common affliction. In the same year, Robins and Jankelson demonstrated radiographically that gastroesophageal reflux was associated with epigastric and substernal discomfort in 90% of their patients with hiatal hernia. In 1930, Max Ritvo, a Boston radiologist, published a series of 60 cases drawn from 8,000 barium studies he had performed. Ritvo stated that the cause of the "acquired esophageal orifice hernia" is the increased intra-abdominal tension, which can be caused by conditions such as constipation, pregnancy and obesity. He also reported epigastric pain, heartburn, nausea, vomiting and regurgitation as clinical correlates of hiatal hernia in the majority of his patients but concluded that "the complaints are mild and operative measures are only rarely necessary."

Later that year, Moore and Kirklin detailed the appropriate radiologic methods for demonstrating the presence of hiatal hernias: the employment of recumbent postures and the manual pressure over the abdomen. The acceptance of hiatal hernia as a distinct entity was not universal. Kirklin pointed out that the clinical significance of small hernias demonstrable only under more or less artificial conditions has not been fully determined and Sauerbruch et al. in 1932 reported that the radiologic appearance of hiatal hernia occurs in the absence of any symptoms and considered hiatal hernia an artifact.

First Operative Trials

In 1919, Angelo Soresi published the first treatise describing elective surgical repair of hiatus hernia entitled Diaphragmatic Hernia. Its Unsuspected Frequency: Its Diagnosis: Technique for Radical Cure. The aim of his paper was to call the attention of interns and of surgeons to the frequency of diaphragmatic hernias especially small ones, because patients suffering from this condition are not properly treated. This lack of interest is not easily explained, because diaphragmatic hernias give rise to so many complicated and serious symptoms, which, if not properly attended to, will lead the patient to an unfortunate life and premature death. Soresi s paper proceeds with almost messianic zeal to attribute a wide variety of abdominal symptoms to the presence of even the smallest hiatal hernias. In spite of being melodramatic, Soresi s report details the original abdominal approach to the hiatus. His operation consisted of reduction of the hernia and closure of the opening of the diaphragm. He described his operative technique such that the suture has to close in the most perfect manner the opening of the diaphragm especially around the organs that pass through it, esophagus, vena cava, aorta, but without compressing the important organs just mentioned. If the esophagus or the aorta are found in the gap the stitch is somewhat modified: the needle goes through the most superficial layer of the organ that is included in the gap, but the surgeon must be exceedingly careful not to enter the lumen of the organ.

Following Soresi s report, interest in the surgical treatment of hiatal hernia grew. Stuart Harrington and his colleagues at the Mayo clinic published their experience treating 27 patients in 1928. The Mayo clinic group refined the criteria for patient selection, choosing to observe patients whose hiatal hernias were discovered radiographically during the course of a general examination. Patients felt to have symptomatic diaphragmatic hernias were usually approached transabdominally. The operation was basically the one that Soresi had used 10 years earlier. Harrington emphasized that: closure of the hernia opening is essential for the relief of symptoms. When he was not able to close the diaphragm, he sutured the herniated viscera to the abdominal wall, a procedure that he called palliative. He also introduced phrenic neurectomy via a cervical incision as an adjunct in cases of large hiatal hernias where the hiatus was difficult to close. He reported zero mortality, and his recurrence rate was 12.5%. The correction of hiatus hernia by paralyzing the left hemidiaphragm was tried by other surgeons over the next two decades. The results were unpredictable and the method was finally abandoned.

In 1950, Richard Sweet from Massachusetts General Hospital published his transthoracic technique. Sweet, using many of the principles developed in the treatment of inguinal hernias, reduced the hernia, crushed the phrenic nerve and plicated the hernia sac. He then narrowed the hiatus with heavy silk sutures until he could get his index finger between the esophagus and the rim of the hiatus. Sweet suggested that in some cases an additional suture of fascia lata obtained from the left thigh should be used to reinforce the repair. This technique may be the predecessor of the current use of pledgeted sutures. Sweet also reported that in some cases the esophagus was congenitally short, preventing reduction of the stomach into the abdomen. In these cases, he suggested that no attempt to alter the location of the cardia and stomach needed to be made. Two years later, he reported a series of 111 consecutive cases of hiatal herniorrhaphies with good short-term results.

HIATAL HERNIA IN THE SECOND HALF OF THE 20TH CENTURY

Although it seems surprising to today s surgeons, a physiologic link between hiatal hernia and gastroesophageal reflux had yet to be made as the second half of the 20th century began. Surgical procedures were based solely on anatomic observations. Many surgeons believed that symptoms in patients with hiatal hernias emanated from pinching of the stomach as it traversed the hiatus. The surgeons of the first half of the 20th century had focused on correcting an anatomic defect. To their dismay, many patients had successful restoration of anatomy but persisting symptoms. Surgeons were inclined to focus on the degree of hiatal closure as responsible for persisting symptoms, and some, such as Saeurbruch in Berlin, went so far as to enlarge the hiatal orifice to relieve the presumed constricting effect of the hiatal fibers on the herniated stomach.

Philip Allison in Leeds and Norman Barrett in London (Fig. 1.8) played a major role in changing the established perception of the sliding hernia from that of an anatomic mechanical condition to a functional physiologically based disorder and established that reflux esophagitis and



Fig. 1.8: Allison and Barrett

its complications were the physiologic consequences of anatomic abnormalities. Allison should be credited for initiating the modern era of antireflux surgery. In his classic paper published in 1951, he aimed to emphasize the relation between the altered physiology at the cardia and a common form of indigestion consisting mainly of heartburn, gastric flatulence and postural regurgitation. He attributed the occurrence of these symptoms to reflux esophagitis due to incompetence of the gastroesophageal junction and stated that the cause of the incompetence is a sliding hernia of the stomach through the esophageal hiatus of the diaphragm into the posterior mediastinum. Allison focused on the crural sling as the key factor in preventing reflux. He believed these crural fibers functioned as a pinchcock to prevent reflux. His transthoracic surgical technique consisted of: (1) reduction of the herniated cardia back into the abdomen; (2) retention of the cardia to that position by suturing the phrenoesophageal ligament and peritoneum to the abdominal aspect of the diaphragm; (3) approximation and light suture of the crural fibers behind the esophagus. Allison emphasized the importance of light suture so that the muscle fibers of the hiatus could continue to function. Allison classified hiatal hernia into two types: (1) the sliding hernia and (2) the paraesophageal or rolling, now more commonly designated as the type I and type II, and he observed that these two types give rise to different symptoms and had a different prognosis.

Allison supported the surgical treatment of sliding hernias for two reasons. Primarily, because the symptoms from reflux esophagitis were distressing to the patient and also because he had noticed that persistent superficial inflammation is liable to be complicated by ulceration or fibrosis with stricture formation, when the surgical treatment may become unavoidable and much more formidable. Over a 5-year period, Allison saw 204 patients with hiatal hernias, and he had operated upon 33 patients with hiatal hernias and esophagitis but no stenosis. There was 1 death, and 30 of 32 surviving patients had excellent short-term results. Twenty-two years later, he reviewed 421 of his own cases and reported a recurrence of the hernia or gastroesophageal reflux in 49% of his sliding hiatal hernia repairs. He was courageous enough to report this to the American Surgical Association meeting in 1973.

Whereas Allison focused on reduction of the hiatal hernia and proper closure of the diaphragmatic sling, Norman Barrett focused on restoration of the cardioesophageal angle as the critical element in the prevention of reflux. Long before fiberoptic endoscopies could confirm it, he postulated the presence of a fold of mucosa at the gastroesophageal junction that functioned as a flap valve. Restoration of the cardiophrenic angle was therefore the key objective of an antireflux operations, a concept that became central to subsequent operations developed by Belsey and Hill. Apart from his classic report on the columnar lined esophagus and its ulcerative

complications, Barrett also emphasized the frequency of sliding hiatus hernia, the occurrence of paraesophageal hernia, and he discussed the way in which acid reflux is prevented. He reported, To summarize my views about the rationale of operations to cure reflux esophagitis, I believe that the hernia should be reduced because its presence permits reflux; the esophageal hiatus may sometimes require diminishing in size in the hopes that this maneuver will help to prevent a recurrence of the hernia; the esophagogastric angle should be reconstituted by fixing the cardia below the diaphragm and so allowing the fundus of the stomach to balloon up under the dome. Barrett considered the phrenoesophageal ligament of no importance, and he believed that the left gastric artery and its mesentery were the anatomic structures that maintained the stomach under the diaphragm in normal people. Barrett's contributions stimulated surgeons to design procedures aimed at improving the function of the cardia rather than simply focusing on hernia reduction.

The confluence of two streams of thought, the anatomic focusing on herniation and the physiologic focusing on acid reflux, were critical to the development of modern hiatal hernia surgery. The identification of the lower esophageal sphincter and use of manometry were reported in 1956. Esophageal pH monitoring would come two decades later. These tools linked anatomy and physiology to permit accurate diagnosis of reflux disease and provided an objective standard for evaluation of surgery. In the midst of this physiologic revolution, Rudolph Nissen and Ronald Belsey developed the operations used by most surgeons in the 21st century.

The development of the Nissen fundoplication has been falsely described as an example of progress in surgery by accident. In fact, Rudolf Nissen was a man of great power of observation, and his pioneer contribution was the result of 30 years of surgical trials (Fig. 1.9). Nissen, the son of a Prussian physician, began his career in Munich as an associate to Professor Sauerbruch. Although Nissen was to be remembered for the development of his antireflux operation, he began his career performing surgery for victims of tuberculosis. He was the first Western surgeon to perform a successful pneumonectomy, reporting this in 1931, 2 years before Evarts Graham did so in the United States. When Hitler enacted the Jewish Boycott in 1933, Nissen fled from Berlin and became chief of surgery in Istanbul. In 1936, he treated a 28-year-old man with a distal esophageal ulcer penetrating into the pericardium. The procedure performed was a transpleural mobilization and resection of the distal esophagus and cardia with insertion of the esophageal stump into the gastric fundus. In an effort to prevent leakage of the esophagogastric anastomosis, he implanted the distal segment of the esophagus into the anterior wall of the gastric body using the Witzel technique used for gastrostomies. The patient survived, and Nissen noted in follow-up that the patient's reflux symptoms had been abolished. In spite of this success, Nissen used the techniques of Harrington and Allison during the 1940s and early 1950s for treatment of hiatal hernias, but he was disappointed by the high incidence of relapses. In 1946, while chief of surgery at Maimonides Hospital in New York, the famous American radiologist Gustav Bucky came to see Nissen, who is desperately ill from an incarcerated paraesophageal hernia. Nissen reluctantly agreed to operate on Bucky but judged that Bucky was too frail to tolerate a thoracotomy. In spite of the fact that nearly all hiatal hernia repairs had been performed transthoracically, Nissen performed a laparotomy, reduced the hernia, and performed an anterior gastropexy. The patient recovered completely and remained free of symptoms throughout a follow-up of more than 15 years. At that time, Nissen felt that this procedure might prove effective in high-risk elderly patients, and he considered accentuation of the angle of His as the mechanism of action of gastropexy. It is unknown if Nissen was aware that Boerema had published the first description of anterior gastropexy (i.e. the fixation of the lesser curvature of the stomach to the anterior abdominal wall) as the sole necessary procedure in the surgical repair of hiatus hernia one year previously. Although transabdominal hernia reduction and gastropexy remain useful adjuncts in the surgical management of paraesophageal hernias, the benefits of anterior gastropexy proved to be short lived for the management of sliding hernias and reflux symptoms. In 1955, disillusioned with the results of gastropexy, Nissen recalled the success of his procedure in Istanbul and opted to create a similar Witzel tube around the esophagus, although this time without esophageal resection. Furthermore, given the large experience with gastroplasty, he decided to perform this procedure transabdominally. Now in Basel, Switzerland, he operated upon a 49-year-old woman with a 3-year history of reflux esophagitis without a hiatal hernia. The phrenoesophageal ligament

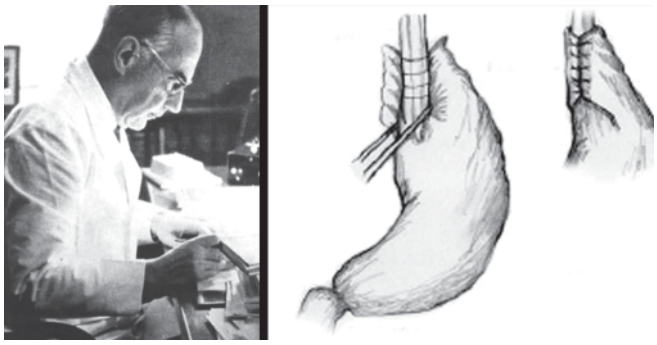

Fig. 1.9: Rudolf Nissen and his technique

was divided and the esophagus mobilized, while the short gastric arteries were not divided. Using his right hand, he then passed the gastric fundus behind the stomach through an opening provided by the divided gastrohepatic ligament. A fundoplication was performed wrapping both anterior and posterior walls of the stomach around the lower 6 cm of the esophagus. He used four or five interrupted sutures, one or more of which also incorporated part of the anterior wall of the esophagus. The wrap was performed around a large-bore indwelling intraesophageal stent. The clinical outcome was excellent and was reproduced in a subsequent patient. These two cases were published in 1956, and Nissen named the operation gastroplication.

Whereas Nissen relied on his keen sense of memory and intuition, the Belsey Mark IV operation was the culmination of years of observations in the Frenchay endoscopy unit in Bristol, England. Since late 1940s, Ronald Belsey had embarked upon a program of surgical trials based on his endoscopic observations. Using a rigid endoscope and examining the sedated but awake patient in the sitting position, Belsey came to appreciate that reflux was the result of a patulous cardia. Reduction of the cardia below the diaphragm was felt to be a key to maintaining the cardiophrenic angle and hence competence of the lower esophageal sphincter. These observations prompted him to design a new procedure based on the assumption that the restoration and maintenance of an intra-abdominal segment of esophagus could play a role in the control of reflux. Belsey assumed that a transthoracic approach was mandatory because extensive mobilization of the esophagus would be routinely necessary to restore the intra-abdominal esophageal segment without tension. He focused his efforts on the design of a procedure taking into account two main issues: (1) the necessary length of intra-abdominal esophagus to be restored; (2) the simplest means of maintaining this segment intra-abdominally. Belsey believed that the application of surgical techniques evolved in animal models was unrewarding and consequently these two main issues would have to be solved by surgical trial and error. Additionally, he considered long-term follow-up to be the only means for the assessment of a new surgical technique.

Belsey followed his own principles rigorously, and perhaps the most salient lesson derived from his work is his remarkable restraint in deferring publication until the long-term success of his operation was assessed in a large number of patients. He called his final procedure Mark IV to serve notice that this was not his first thought (and possibly not his last) on the subject but the result of a series of surgical trials designated as Marks I, II and III. Mark I was essentially Allison's procedure, while Marks II and III represented various degrees of fundoplication. These initial three techniques were tested during the period 1949 to 1955, and the results were unsatisfactory in about a third of the patients. There were also seven postoperative deaths. The final Mark IV operation was adopted in 1952; Belsey published his findings only after he became sufficiently satisfied with the durability of the technique he had developed. Thus, in 1961, Hiebert reported the results of 71 surgically treated patients with symptomatic reflux but no demonstrable hernia, and 6 years later in a classic and extremely influential paper, Skinner and Belsey reviewed the long-term follow-up of 1,030 patients, most with hiatal hernia. With a minimum follow-up of 5 years, 85% of patients had no reflux symptoms (Fig. 1.10).

Another significant development occurred in 1957, when J Leigh Collis in Birmingham, England, published his innovative operation for treating the difficult problem of the irreducible hiatal hernia, esophagitis and stricture. Collis believed that the acute angle of implantation of the

Fig. 1.10: Belsey and Hiebert

esophagus into the stomach which in turn is produced by the normally functioning crural muscle can be effective alone in controlling gastroesophageal competence. His goal was to design a procedure to avoid the complicated resectional operations and the endless esophageal dilatations, especially in the frail and aged. Collis gastroplasty created controversy and did not prove to fully control reflux esophagitis. Many surgeons reported significant early and late complications, some resulting from the creation of an iatrogenic Barrett's esophagus. The technique, however, was not without significant merit. Robert Henderson and Griffith Pearson in Toronto in 1976 combined Collis gastroplasty with the Belsey procedure in a group of difficult patients (previously failed antireflux operation and a shortened esophagus, stricture, transmural ulcerative esophagitis, large combined sliding and paraesophageal hernia difficult to be reduced without tension) and reported outstanding results. Mark Orringer and Herbert Sloan in Ann Arbor combined Collis gastroplasty with the Nissen 360 degree antireflux gastric wrap. The Ann Arbor group also published excellent results. The problem of the firm, fixed, fibrous strictures occurring as a result of peptic esophagitis was also addressed by Alan Thal, who described his technique using a gastric patch in 1965.

While Nissen was performing his initial fundoplications, Lucius Hill carefully studied the physiology and anatomy of the gastroesophageal junction and esophageal hiatus. He further elucidated the mechanism of gastroesophageal reflux using manometry to demonstrate the existence of a high-pressure zone in the terminal esophagus. He also was a pioneer in the use of pH sensing to confirm the diagnosis of gastroesophageal reflux preoperatively and then confirm the physiologic success of his operations. Hill's extensive studies of the anatomy of the esophageal hiatus in cadavers led him to conclude that the strongest portion of the phrenoesophageal membrane lay posteriorly both as direct attachments to the esophagus and the median arcuate ligament. Combining his understanding of lower esophageal sphincter function and anatomy, Hill demonstrated that maintenance of the cardiophrenic angle was the essential element in the control of gastroesophageal reflux. Hill then designed an operation that restored the angle of His by reapproximating the phrenoesophageal bundles and anchoring them to the median arcuate ligament. Hill was as passionate as his rivals, Nissen and Belsey, in proclaiming the superiority of his technique. His original report, Newer Concepts of the Pathophysiology of Hiatal Hernia and Esophagitis, lambasted many of his predecessors for poor follow-up and lack of objective determination of reherniation or reflux. He wrote that these points indicate that current repair of hiatal hernia is in about the same state as repair of inguinal hernia at the time of Bassini and Halsted in 1888. Their recurrence rates for inguinal hernia were lower in 1888 than they are for hiatal hernia in current documented reports. In 1967, Hill published his 8 years' experience with the technique he had developed. He designated his operation as posterior gastropexy, and this operation became the only gastropexy procedure that has withstood the test of time. In Hill's initial experience, there was a high incidence of postoperative dysphagia, so Hill subsequently performed the procedure using intra-operative manometry. This unique approach allowed tailoring of the anchoring sutures to achieve a lower esophageal sphincteric pressure of 35 mm Hg or less. In the subsequent 30 years, Hill continued to study the anatomic and physiologic aspects of gastroesophageal reflux. In the mid 1990s, he described the flap valve mechanism of the cardia, an anatomic feature so important it is now incorporated into anatomic textbooks. Additionally, he proposed a grading system of the flap valve mechanism that correlated with the patient's reflux status better than the measurement of the lower esophageal sphincter pressure alone.

In the 1970s, Nissen's fundoplication was rapidly adopted worldwide and became the most popular antireflux operation. The original operation underwent modifications by Nissen himself, as well as by other surgeons. Closure of the hiatus was recognized as an essential part of all antireflux procedures to avoid herniation of the fundoplication. An important modification was described by Rudolf Nissen's favorite pupil, Mario Rossetti (Fig. 1.11A). This was the creation of the fundoplication (Fig. 1.11B) using only the anterior wall of the gastric fundus. As Hill was fond of pointing out, dysphagia was extremely common following a Nissen fundoplication. In Europe, construction of a partial wrap (less than 360 degrees) was proposed by Dor et al. and Andre Toupet in an effort to minimize the postoperative symptoms plaguing patients who underwent Nissen fundoplication. When Toupet introduced this concept in the early 1960s, he was harshly criticized, and his procedure received little attention until the laparoscopic era. In the United States, Donahue et al. and Demeester and Johnson also worked to improve on Nissen's operation. They

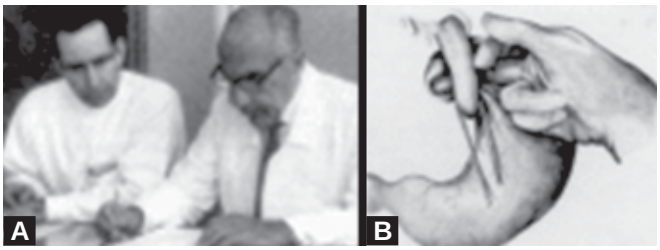

Figs 1.11A and B: (A) Mario Rossetti and Rudolf Nissen (B) Their technique of fundoplication

were the first to truly understand the physiologic mechanism of Nissen's fundoplication and modified it by division of short gastric vessels and the creation of a loose floppy wrap. Demeester and Johnson evaluated the optimal length of the wrap and convincingly showed that a loose wrap of just 2 cm was sufficient for reflux suppression and reduced the incidence of troublesome postoperative bloating and dysphagia. It is this modification of the original Nissen fundoplication that is most commonly performed in the laparoscopic era.

The development of minimally invasive surgical techniques has led to a dramatic increase in the number of antireflux operations being performed. The widespread availability of physiologic testing with esophageal motility studies and 24-hour pH probe studies has greatly improved the identification of those patients likely to benefit from surgery. A description of the many significant developments in the laparoscopic era is beyond the scope of this review. Modern surgeons working in an era of animal rights, privacy protection and public wariness of clinical trials will be hard pressed to duplicate the feats of the pioneers in hiatal hernia surgery. The lessons learned about the physiologic basis of gastroesophageal reflux and the need for long-term follow-up will need to be applied as new techniques are introduced and marketed. It will be interesting to see how the 21st century surgeons adjust to the current environment to achieve the high standards set by their predecessors.

BIBLIOGRAPHY

1. Akerlund A, Onnell H, Key E. Hernia diaphragmatica hiatus oesophagei vom anastomischen und roentgenologischen gesichtspunkt. Acta Radiol. 1926;6:3-22.
2. Allison PR. Hiatus hernia (a 20-year retrospective survey). Ann Surg. 1973;178(3):273-6.
3. Allison PR. Reflux esophagitis, sliding hiatal hernia and anatomy of repair. Surg Gynecol Obstet. 1951;92(4):419-31.
4. Annandale T. A case in which a reducible oblique and direct inguinal and femoral hernia existed on the same side and was successfully treated by operation. Edinburgh Med J. 1876;21:1087-91.
5. Atkinson M, Ingelfinger FJ, Kramer P. The motility and pharmacology of the oesophagus in cardiospasm. Gastroenterologia. 1956;86(3):174-8.
6. Barrett NR. Hiatus hernia: a review of some controversial points. Br J Surg. 1954;42(173):231-43.
7. Bassini E. Nuovo metodo per la cura radicale dell'ernia inguinale. Arch F Klin Chir. 1890;40:429-76.
8. Bettex M, Oesch I. The hiatus hernia saga. Ups and downs in gastroesophageal reflux: past, present and future perspectives. Pediatr Surg. 1983;18(6):670-80.
9. Billard CM. Traite des Maladies des Enfans Nouveaux-Nes et a la Mamelle: Fonde sur de Nouvelles Observations Cliniques et d'Anatomie Pathologique, Faites a l'Hopital des Enfans-Trouves de Paris, dans le Service de M. Baron. Paris: JB Bailliere; 1828.
10. Boerema I, Germs R. Fixation of the lesser curve of the stomach to the anterior abdominal wall after reposition of the hernia through the esophageal hiatus. Arch Chir Neerl. 1955;7(4):351-9.
11. Bowditch HI. A Treatise on Diaphragmatic Hernia. Buffalo: Jewett Thomas; 1853.
12. Cannon WB, Moser A. The movements of the food in the esophagus. Am J Physiol. 1898;1:435-44.
13. Carbajo MA, Martin del Olmo JC, Blanco JI, et al. Laparoscopic treatment vs open surgery in the solution of major incisional and abdominal wall hernias with mesh. Surg Endosc. 1999;13(3):250-2.
14. Cheatle GL. An operation for the radical cure of inguinal and femoral hernia. Br Med J. 1920;2(3107):68-9.
15. Code CF, Fyke FE Jr, Schiegel JF. The gastroesophageal sphincter in healthy beings. Gastroenterologia. 1956;86(3):135-50.
16. Collis JL. An operation for hiatus hernia with short esophagus. J Thorac Surg. 1957;34(6):768-73.
17. Cooper A. The Lectures of Sir Astley Cooper, Bart FRS. Surgeon to the King, on the Principles and Practice of Surgery, with Additional Notes and Cases by Frederick Tyrrell. London: Thomas and George Underwood; 1824-7.
18. DeMeester TR, Bonavina L, Albertucci M. Nissen fundoplication for gastroesophageal reflux disease: evaluation of primary repair in 100 consecutive patients. Ann Surg. 1986;204(1):9-20.
19. Demeester TR, Johnson LF. Evaluation of the Nissen antireflux procedure by esophageal manometry and 24 hours pH monitoring. Am J Surg. 1975;129(1):94-100.
20. Donahue PE, Larson GM, Stewardson RH, et al. Floppy Nissen fundoplication. Rev Surg. 1977;34(4):223-4.
21. Dor J, Humbert P, Dor V, et al. The role of the modified Nissen procedure in the prevention of reflux following Heller's extramucosal cardiomyotomy. Mem Acad Chir. 1962;88:877-82.
22. Ebbell B (transl.). The Ebers Papyrus. The Greatest Egyptian Medical Document. London: H. Milford and Oxford University Press; 1937. pp. 17 and 123.
23. Franklin ME, Dorman JP, Glass JL, et al. Laparoscopic ventral and incisional hernia repair. Surg Laparosc Endosc. 1998;8(4):294-9.
24. Friedenwald J, Feldman M. Report of an interesting type of diaphragmatic hernia of the cardia of the stomach through the esophageal orifice. Am Med Sci. 1925;170:263.
25. Fruchaud HR. Anatomie chirurgicale des hernies de l'aine. Paris: G. Doin; 1956.
26. Goepel R. Ueber die Verschliessung von Bruchpforten durch Einheilung geflochtener, fertiger Silberdrahtnetze (Silberdrahtpelotten). Verh Dtsch Ges Chir. 1900;19:174.
27. Habibulla KS, Collis JL. Intraluminal pressure, transmucosal potential difference and pH studies in the oesophagus of patients before and after Collis repair of a hiatal hernia. Thorax. 1973;28(3):342-8.
28. Hamperl H. Peptische oesophagins (Peptic esophagitis). Verh Dtsch Pathol. 1934;27:208.
29. Harrington SW. Diaphragmatic hernia. Arch Surg. 1928;16:386-415.

30. Harrington SW. The surgical treatment of the more common types of diaphragmatic hernia: esophageal hiatus, traumatic, pleuroperitoneal hiatus, congenital absence and foramen of Morgagni: report of 404 cases. Ann Surg. 1945;122(4):546-68.
31. Hedblom CA. Diaphragmatic hernia: a study of 378 cases in which operation was performed. JAMA. 1925;85:947.
32. Heydorn W. Hernia. In: James EC, Corry RJ, Perry JF (Eds). Principles of Basic Surgical Practice. St Louis: Mosby; 1987. pp. 351-2.
33. Hiebert CA. Surgical management of esophageal reflux and hiatal hernia, 1951. Ann Thorac Surg. 1991;52(1):159-60.
34. Hill LD, Kozarek RA, Kraemer SJ, et al. The gastroesophageal flap valve: in vitro and in vivo observations. Gastrointest Endosc. 1996;44(2):541-7.
35. Hill LD, Kozarek RA. The gastroesophageal flap valve. J Clin Gastroenterol. 1999;28(3):194-7.
36. Hill LD, Tobias J, Morgan EH. Newer concepts of the pathophysiology of hiatal hernia and esophagitis. Am J Surg. 1966;111(1):70-9.
37. Hill LD. An effective operation for hiatal hernia: an 8-year appraisal. Ann Surg. 1967;166(4):681-92.
38. Hochberg LA. Thoracic Surgery before the 20th Century. New York: Vantage Press; 1960.
39. Laennec RTH. De l'auscaltation Mediate, ou Traite du Diagnostic des Maladies des Poulmons et du Coeur, Fonde Principalement sur ce Nouveau Moyen d'Exploration. Paris: Chez J.-A. Brosson et J.-S. Chaude; 1819.
40. LeBlanc KA, Booth WV. Laparoscopic repair of incisional abdominal hernias using expanded polytetrafluoroethylene: preliminary findings. Surg Laparosc Endosc. 1993;3(1):39-41.
41. Lichtenstein IL. Hernia Repair without Disability, 2nd edition. St Louis: Ishiyaku Euroamaerica, Inc.; 1986.
42. Liebermann-Meffer, Stein H. In: Nissen R (Ed). The World Revolution of Fundoplication. St Louis, MI: Quality Medical Publishing Inc.; 1999.
43. Mackenzie M. A Manual of Diseases of the Throat and Nose: including the Pharynx, Larynx, Trachea, Oesophagus, Nose and Naso-Pharynx. London: J & A Churchill; 1884.
44. Moore AB, Kirklin BR. Progress in the roentgenological diagnosis of diaphragmatic hernia. JAMA. 1930;95:1966-9.
45. Nissen R. Die transpleurale Resection der Kardia. Dtsch Z Chir. 1937;249:311-6.
46. Nissen R. Eine einfache Operation zur Beeinflussung der Refluxeosophagitis. Schweiz Med Wochenschr. 1956;86(Suppl 20):590-2.
47. Nissen R. Exstirpation eines ganzen Lungenflugels. Dtsch Zbl Chir. 1931;58:3003-6.
48. Nissen R. Gastropexy as the lone procedure in the surgical repair of hiatus hernia. Am J Surg. 1956;92(3):389-92.
49. Nissen R. Reminiscences: reflux esophagitis and hiatal hernia. Rev Surg. 1970;27(5):307-14.
50. Nyhus LM, Stevenson JK, Listerud MB, et al. Preperitoneal herniorrhaphy; a preliminary report in 50 patients. Western J Surg. 1959;67(1):48-54.
51. Orringer MB, Sloan H. An improved technique for the combined Collis-Belsey approach to dilatable esophageal strictures. J Thorac Cardiovasc Surg. 1974;68(2):298-302.
52. Pearson FG, Henderson RD. Long-term follow-up of peptic strictures managed by dilatation, modified Collis gastroplasty and Belsey hiatus hernia repair. Surgery. 1976;80(3):396-404.
53. Phelps AM. A new operation for hernia. NY Med J. 1894;60:291.
54. Ponka JL. Significant contributions toward understanding and sound treatment of hernias. In: Ponka JL (Ed). Hernias of the Abdominal Wall. Philadelphia: WB Saunders Co; 1980. pp. 1-17.
55. Quincke H. Esophageal ulcers from digestive juice (ulcus oesophagi ex digestione). Dtsch Arch Klin Med. 1879;24:72.
56. Ritvo M. Hernia of the stomach through the esophageal orifice of the diaphragm. JAMA. 1930;94:15-21.
57. Robins SA, Jankelson IR. Cardio-esophageal relaxation. JAMA. 1926;87:1961-4.
58. Rokitansky C. Quoted by Nissen R. In Fundoplication und Gastropexie Bei Refiuxkrankheit und Hiatushernie. New York: G Thieme Verlag Stuggart; 1981.
59. Sauerbruch F, Chaoul H, Adam A. Hiatus hernia. Dis Med Wochenschr. 1932;82:1709-12.
60. Schwarz GS. Historical aspects of the anatomy of the cardia with special reference to hiatus hernia. Bull N Y Acad Med. 1967;43(2):112-25.
61. Sheehan JE. Ulcer of the esophagus from the standpoint of an endoscopist. Med Rec. 1920;97:319.
62. Skinner DB, Belsey RH. Surgical management of esophageal reflux and hiatus hernia. Long-term results with 1,030 patients. J Thorac Cardiovasc Surg. 1967;53(1):33-54.
63. Soresi AL. Diaphragmatic hernia: its unsuspected frequency: diagnosis and technique for radical cure. Ann Surg. 1919;69(3):254-70.
64. Stoppa RE, Petit J, Henry X. Unsutured Dacron prosthesis in groin hernias. Int Surg. 1975;60(8):411-2.
65. Stoppa RE, Rives JL, Warlaumont CR, et al. The use of Dacron in the repair of hernias of the groin. Surg Clin N Am. 1984;64(2):269-85.
66. Sweet RH. Diaphragmatic hernia. In: Sweet RH (Ed). Thoracic Surgery. Philadelphia: WB Saunders; 1950. pp. 316-34.
67. Sweet RH. Esophageal hiatus hernia of the diaphragm: anatomical characteristics, technique of repair, results of treatment in 111 consecutive cases. Ann Surg. 1952;135:1-13.
68. Thal AP. A unified approach to surgical problems of the esophagogastric junction. Ann Surg. 1968;168(3):542-50.
69. Tileston W. Peptic ulcer of the oesophagus. Am J Med Sci. 1906;132:240-65.
70. Toupet A. Technique d'eosophago-gastroplastie avec phreno-gastropexie dans la cure radicales des hernies hiatales et comme complement de l'operation de Heller dans les cardiospasmes. Mem Acad Chir. 1963;89:394-9.
71. Usher FC, Gannon JP. Marlex mesh: a new plastic mesh for replacing tissue defects: I. Experimental Studies. Arch Surg. 1959;78(1):131-7.
72. Usher FC. Hernia repair with knitted polypropylene mesh. Surg Gynecol Obstet. 1963;117:239-40.
73. Vinson PP. Oesophageal stricture following the vomiting of pregnancy. Surg Gynecol Obstet. 1921;33:412.
74. Winklestein A. Peptic esophagitis: a new clinical entity. JAMA. 1935;104:906.
75. Witzel O. Ueber den Verschluss von Bauchwunden und Bruchpforten durch versenkte Silberdrahtnetze (Einheilung von Filigranpelotten). Centralbl Chir Leipz. 1900;27:257.
76. Zenker FA, von Ziemsen H. Diseases of the esophagus. In: Cyclopedia of the Practice of Medicine. New York: William Wood; 1878. pp. 1-214.