

Stapled hemorrhoidopexy: Clinical results of 65 cases

Stapler hemoroidopeksi: 65 olguda klinik sonuçlar

Ahmet Pergel, Ahmet Fikret Yücel, İbrahim Aydın, Dursun Ali Şahin

ABSTRACT

Objectives: To present results of our patients underwent stapled hemorrhoidopexy due to hemorrhoidal disease and discuss in accompaniment with the literature.

Material and methods: The patients, who diagnosed by 3rd-4th degree hemorrhoidal disease and underwent hemorrhoidopexy with Longo method between January, 2009 and April, 2011, were included. All data were prospectively collected and retrospectively examined. The patients were evaluated in terms of demographic properties, complaints on admission, and postoperative complications.

Results: Forty-three (66%) of 65 patients were male, 22 (34%) were female. The mean age was 38±11.9 (range:23-76) years. The most frequent complaints were bleeding, swelling, itching, pain, constipation respectively. Third degree hemorrhoid was present in fifty-eight (89%) patients, 4th degree hemorrhoid was in 7 (11%) patients. The mean operation duration was 37.6±8.1(range:24-55) minutes, the mean hospitalization duration was 27±7.8 (range:20-76) hours. One or more complication developed in total 17 (26%) patients. As complication, bleeding was determined in 13 (20%) patients, pain was in 6 (9%), urinary retention was in 2 (3%), tenesmus was in 3 (5%), external hemorrhoidal thrombosis was in 1 (2%), and recurrence was in 4 (6%).

Conclusions: The patients can return their daily activities early with stapled hemorrhoidopexy because of less pain and quick recovery period. We consider that appropriate patient selection and proper application of the technique are important in the success of this method. Particularly in 3rd degree hemorrhoidal disease, Longo's technique can be suggested as an alternative to classical methods. *J Clin Exp Invest 2012; 3 (3): 340-344*

Key words: Hemorrhoidal disease, stapled hemorrhoidopexy, Longo's procedure

INTRODUCTION

Hemorrhoidal disease is a disease affecting social life negatively and found in approximately 4-20% of the population. A lot of methods such as plastic

ZET

Amaç: Hemoroidal hastalık sebebiyle stapler hemoroidopeksi uyguladığımız hastalarımızın sonuçlarını sunmak ve literatür eşliğinde tartışmak.

Gereç ve yöntem: Ocak 2009- Nisan 2011 tarihleri arasında 3-4. derece hemoroidal hastalık tanısı konan ve Longo yöntemiyle hemoroidopeksi uygulanan hastalar çalışmaya dahil edildi. Tüm veriler prospektif toplanıp retrospektif olarak incelendi. Hastalar; demografik özellikler, başvuru sırasındaki şikayetler, ameliyat sonrası komplikasyonlar açısından değerlendirildi.

Bulgular: Toplam 65 hastadan 43 (% 66)'ü erkek, 22 (% 34)'si kadındı. Ortalama yaş 38±11.9 (23-76) yıl idi. Olguların en sık başvuru şikayetleri sıklık sırasına göre kanama, şişlik, kaşıntı, ağrı, kabızlık şeklinde idi. Elli sekiz (% 89) hastada 3. derece, 7 (%11) hastada 4. derece hemoroid mevcuttu. Ortalama ameliyat süresi 37.6±8.1(24-55) dakika, ortalama yatış süresi 27±7.8 (20-76) saat idi. Toplam 17 (% 26) hastada bir ya da daha fazla komplikasyon gelişti. Komplikasyon olarak 13 (% 20) hastada kanama, 6 (%9)'sında ağrı, 2 (% 3)'sinde idrar retansiyonu, 3 (% 5)'ünde tenezm, 1 (% 2)'inde eksternal hemoroidal tromboz, 4 (%6)'ünde ise nüks saptandı.

Sonuç: Stapler hemoroidopekside ağrının az ve iyileşme sürecinin hızlı olması nedeniyle hastalar günlük aktivitelerine erken dönebilmektedirler. Bu yöntemin başarısında uygun hasta seçimi ve tekniğin doğru uygulanmasının önemli olduğunu düşünmekteyiz. Özellikle 3.derece hemoroidal hastalıkta Longo tekniği klasik yöntemlere alternatif olarak önerilebilir.

Anahtar kelimeler: Hemoroidal hastalık, stapler hemoroidopeksi, Longo yöntemi

band ligation, sclerotherapy, surgical hemorrhoidectomy (Milligan-Morgan, Ferguson etc.), and stapled hemorrhoidopexy are used in its treatment.¹

In many studies using the method of stapled hemorrhoidopexy, it is reported that postoperative

Department of Surgery, School of Medicine, Recep Tayyip Erdoğan University, 53100, Rize, Turkey

Correspondence: Ahmet Pergel,

Dept. Surgery, School of Medicine, Recep Tayyip Erdoğan University, Rize, Turkey Email: pergelahmet@hotmail.com

Received: 12.05.2012, Accepted: 31.07.2012

Copyright © JCEI / Journal of Clinical and Experimental Investigations 2012, All rights reserved

pain and the need of analgesic is lesser in proportion to other surgical methods and work and daily activities are returned earlier due to short recovery time. However, no difference was reported to be with excisional techniques in terms of postoperative complications and recurrences.²⁻⁶ Nonetheless, studies reporting serious complications such as rectal perforation, chronic anal pain, anal stenosis, sepsis, and hematoma after Longo's method are also present.⁷⁻¹²

The aim in our study was to present results of 3rd and 4th degree hemorrhoid patients in whom we performed stapled hemorrhoidopexy and to discuss in accompaniment of the literature.

MATERIALS AND METHODS

The patients were included into the study, who diagnosed by the 3rd and 4th degree hemorrhoidal disease and in whom hemorrhoidopexy with Longo method was performed between January, 2009 and April, 2011. Operations were carried out by two general surgeons. In the preoperative assessment, physical examination, routine rectosigmoidoscopy, and laboratory tests of the patients were done. The patients, who have a history of clotting disorder, inflammatory bowel disease, diabetes, perianal fistula, anal fissure, abscess, and previous colorectal cancer, were excluded from the study. All data were prospectively collected and retrospectively examined. Although the study was started with 73 patients, 8 patients not coming for long term follow-ups were removed from the study. The patients were evaluated in terms of demographic properties, complaints at the moment of admission, and postoperative complications. The patients were checked at the postoperative 1st, 4th weeks, and 6th months. During controls, complaints were examined along with anorectal examination.

Preoperative bowel prep of the patients was realized. Detailed information about operation technique was given and their informed consent was provided. Operations were carried out under spinal anesthesia in 55 patients and under general anesthesia in 10 patients. 750 mg dose of cefuroxime was intravenously administered to the patients 30 minutes before anesthetic induction. Operations were performed using instant Longo hemorrhoid kit (PPH 03 (33 mm) Ethicon, Endo-Surgery, 04.0, USA) in the lithotomic position. Circular suture was applied 4 cm above the dentate line. During operation, the patients were assessed in terms of bleeding, integrity of stapler line, insufficiency of the procedure. Diclofenac sodium two times a day was

administered intramuscularly for analgesic after operation. In the event of additional analgesic need, meperidine as narcotic analgesic was administered. For pain assessment, Visual Analog Scale (VAS 0: no pain, VAS 10: very severe pain) was used. The patients without complication were discharged by prescribing cefuroxime axetil 500 mg tablet 2 times a day and, if necessary, etodolac 400 mg tablet at the postoperative 1st day to be on the point of use. The patients were checked in the postoperative 1st and 4th weeks and 6th month.

RESULTS

Forty-three (66%) of patients were male, 22 (34%) were female. The mean age was 38±11.9 (range: 23-76) years. As shown in detail by Graph 1, patient complaints at the time they were admitted for surgery included (ranked by frequency): bleeding, swelling, pruritus, pain and, constipation. In two patients, rectal mucosal prolapse was present along with 4th degree hemorrhoid. Eight patients were operated because of thrombosis after medical treatment. 3rd degree hemorrhoid was present in fifty-eight (89%) patients, 4th degree hemorrhoid was in 7 (11%) patients. Demographic properties of the patients were briefed in Table 1.

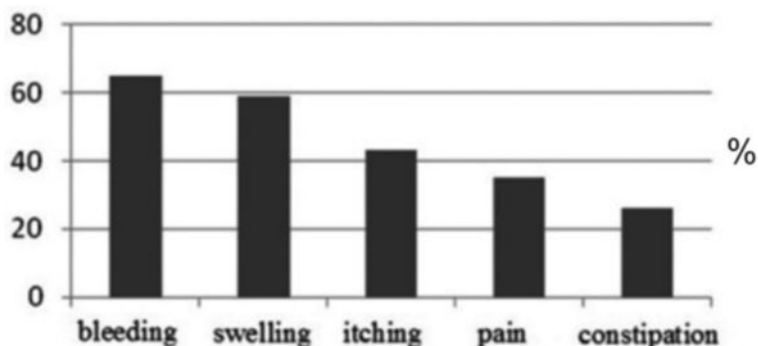
Table 1. Demographic characteristics of patients

Patient characteristics	Number	%
Mean age (SD), yrs	38 (11.9)	
Male	43	66%
Female	22	34%
Grade of hemorrhoid		
Grade 3	58	89%
Grade 4	7	11%

In three patients, additional suture was used due to opening on the stapler line. In two patients, hematoma that developed during circular suture was controlled with tampon and suture. Eleven patients with bleeding on stapler line during operation were sutured for hemostasis. No analgesic was given to the patients describing no pain after operation. Diclofenac sodium 2 times a day was initiated to the patients with pain. According to visual pain score, meperidine was used in 2 patients whose score is 5 and over. In two patients, oral analgesic for more than one month was needed to be used. In two patients, sensation of pain lasting more than 6 months was present. In two patients administered spinal

anesthesia, urinary retention requiring discharging with catheter developed. In two patients, false defecation lasting about 3 months after operation was needed. One patient in whom external thrombosis developed three months later was treated by thrombectomy. Four patients in whom recurrence was determined were excised with Milligan-Mor-

gan's method. Complications were briefed in Table 2. The mean operation duration was calculated as 37.6 ± 8.1 (range: 24-55) minutes, the mean hospitalization duration was 27 ± 7.8 (range: 20-76) hours. At the end of mean follow-up period for nine months, no complaints such as serious bleeding, gas/stool incontinence, or stenosis developed in any patient.



Graph 1. Complaints at admission.

Table 2. Postoperative complications

Complications	Number	%
Bleeding	13	20.0
Pain	6	9.0
Pain lasting longer than six months	2	5.0
Urinary retention	2	3.0
Tenesmus	3	5.0
Thrombosis	1	1.5
Recurrence	4	6.0
Presenting with one or more complication	17	26.0

DISCUSSION

Hemorrhoidectomy is one of the most frequently performed operations of surgery. Postoperative pain is the most frequent and annoying complication. The reason of this is anal region to be hypersensitive and surgical procedure to be carried out in this region. The method of stapled hemorrhoidopexy described by Longo in 1998 is applied from the painless area about 3-4 cm above the dentate line.¹³ In this procedure, mucosa and submucosa are excised in a circular manner. Thus varix clusters are hung up and branches of the superior rectal artery are also cut. Because of painless procedure and rapid recovery, it received attention in a short time and was spread.¹⁴

In the literature, the complication rates related to Longo's technique were reported as 6.4-31%.^{15,16}

Complications that formed mostly in the learning process of this technique are: submucosal hematoma, bleeding, long-term rectal pain, separation on stapler line, external hemorrhoidal thrombosis, rectal perforation, sepsis, and rectovaginal fistula.^{9,10,17} In our study, although our complication rate is 26%, no serious complications were encountered.

One of the most frequently seen early complications during operation is bleeding. Bleeding arises from the submucosal area in the majority of the cases. Additionally, deep sutures may cause hematoma. This may also cause prolongation of the procedure and serious complications which may include even sepsis.^{3,17-19} All of bleedings seen in our study were the bleedings occurring during operation. It was as submucosal hematoma in two cases, as hematoma from the stapler line in others. In the literature, different rates, such as 0.6-10%, associated with postoperative bleeding were reported.^{6,20} In our study, there was no bleeding requiring intervention in any case after operation. As the reason of no bleeding, we consider that the additional suture performed for bleedings like a leakage during the control of stapler line after operation.

Because there is lesser pain after Longo's operation in proportion to the classical method, this technique received attention by many surgeons.^{6,21-25} Because anal region that is sensitive is not touched in the stapler technique and wound healing is faster than the classical method, pain is lesser and lasts for a short time.^{6,26} In order to achieve this, Longo suggested sac suture 3 or 4 cm above the dentate line and it was also defended by many authors.^{6,19,22,27}

In the literature, various rates related to pain between 4% and 7.5% were reported. It is considered that postoperative pain mostly depends on working close to the dentate line, stenosis in the anal canal, mucosal injury, excessive increase in sphincter tonus, and external hemorrhoidal thrombosis.^{9,28} Although pain usually recovers within a few days, in some studies, it was reported to continue up to 15 months at the rate of 1.6-31%.^{9,17,20} In our study, high values in VAS score, seen mostly in the first patients, made think that this method is associated with learning process. Hence the stapler line was observed to be close to the dentate line in controls of some of these patients.

Anal stenosis is one of hemorrhoidopexy's complications been afraid and seen lately. It is considered to be because of retraction depending particularly on fibrosis on the decomposing stapler line and excess spasm of the anal sphincter.¹⁷ In studies in the literature, the rate of anal stenosis in stapled hemorrhoidopexy was reported around %2.^{21,22,29} Anal stenosis was determined in none of our cases in the follow-up period.

Urinary retention is a rare seen complication after hemorrhoidectomy. In studies related to this, rates between 0.3% and 20% were reported.^{12,29} In our series, urinary retention was seen in 2 patients (3%) in whom spinal anesthesia was applied. Drainage was achieved by means of placement of urinary catheter.

One of the most serious complications been afraid after stapled hemorrhoidopexy is pelvic infection and sepsis.^{6,29} Molloy et al. noted that the patients in whom rectal infection developed after stapled hemorrhoidopexy are the patients who do not receive antibiotic and emphasized that antibiotic prophylaxis is so important.³⁰ In our cases, we considered that antibiotic prophylaxis we applied and no presence of a serious accompanying disease are effective in not seeing infection

In the literature, the rate of external hemorrhoidal thrombosis that may be seen in the early or late term after Longo's operation was reported to be around 0.9% and attributed to incompletely-resected hemorrhoidal sinusoids.^{6,12,17} Only in one patient from our cases, external stenosis treated by thrombosectomy was seen.

One of defecation disorders seen after hemorrhoidopexy is tenesmus. In the literature, various rates related to this were reported.²⁰⁻²⁹⁻³¹ In a study, Ortiz et al. determined tenesmus at the rate of 40% and revealed the opinion that this depends on making sac suture at a low level.²⁹ The stapler line close

the dentate line was noted only in 1 patient with complaint of tenesmus in our cases. In others, no reason explaining the complaint was determined. In the literature, various results such as 1-10% with respect to recurrence rates were reported in studies comparing stapled hemorrhoidopexy and conventional hemorrhoidectomy. In some studies comparing these two methods, no statistically significant difference was determined.^{2,26,32} In a study done by Jayaraman et al. by considering 12 studies, they reported high recurrence rates in the long term after stapled hemorrhoidopexy particularly in 4th degree hemorrhoid cases.³³ In our study, low recurrence rate was attributed to small number of 4th degree hemorrhoid cases operated. Besides, we consider that our follow-up duration also is effective on this.

The patients can return their daily activities early in stapled hemorrhoidopexy because of less pain and quick recovery period. We consider that appropriate patient selection and proper application of the technique are important in the success of this method. Particularly in 3rd degree hemorrhoidal disease, Longo's technique can be suggested as an alternative to classical methods.

REFERENCES

1. Demirbaş S, Aktaş O, Öğün İ, Yağcı G. Haemorrhoidectomy by using circular stapler in grade III-IV Hemorrhoids. *T Klin J Med Sci* 2002;22(1):36-41.
2. Ganio E, Altomare DF, Gabrielli F, Milito G, Canuti S. Prospective randomized multicentre trial comparing stapled with open hemorrhoidectomy. *Br J Surg* 2001;88(5):669-74.
3. Boccasanta P, Capretti PG, Venturi M, et al. Randomised controlled trial between stapled circumferential mucosectomy and conventional circular hemorrhoidectomy in advanced hemorrhoids with external mucosal prolapse. *Am J Surg* 2001;182(1):64-8.
4. Rowsell M, Bello M, Hemingway DM. Circumferential mucosectomy (stapled haemorrhoidectomy) versus conventional haemorrhoidectomy: randomised controlled trial. *Lancet* 2000;355(9206):779-81.
5. Gravié JF, Lehur PA, Hutten N, et al. Stapled hemorrhoidopexy versus milligan-morgan hemorrhoidectomy: a prospective, randomized, multicenter trial with 2-year postoperative follow up. *Ann Surg* 2005;242(1):29-35.
6. Sutherland LM, Burchard AK, Matsuda K, et al. A systematic review of stapled hemorrhoidectomy. *Arch Surg* 2002;137(12):1395-406.
7. Maw A, Eu KW, Seow-Choen F. Retroperitoneal sepsis complicating stapled hemorrhoidectomy: report of a case and review of the literature. *Dis Colon Rectum* 2002;45(6):826-8.

8. Wong LY, Jiang JK, Chang SC, Lin JK. Rectal perforation: a life-threatening complication of stapled hemorrhoidectomy: report of a case. *Dis Colon Rectum* 2003;46(1):116-7.
9. Cheetham MJ, Mortensen NJM, Nystom PO, Kamm MA, Phillips RKS. Persistent pain and faecal urgency after stapled haemorrhoidectomy. *Lancet* 2000;356(9231):730-3.
10. Herold A, Kirsch JJ. Pain after stapled haemorrhoidectomy. *Lancet* 2000;356(9231):2187-90.
11. Fazio VW. Early promise of stapling technique for haemorrhoidectomy. *Lancet*. 2000;355(9206):768-9
12. Ravo B, Amato A, Bianco V, et al. Complications after stapled hemorrhoidectomy: can they be prevented? *Tech Coloproctol* 2002;6(2):83-8.
13. Longo A. Treatment of hemorrhoidal disease by reduction of mucosa and hemorrhoidal prolapse with a circular-suturing device: a new procedure. In: *Proceedings of the 6th World Congress of Endoscopic. Rome, Italy: Surgery; 1998.*
14. Terzi C, Füzün M. Anorektumun Benign Hastalıkları. Sayek İ. Temel Cerrahi 3. Baskı. Ankara: Güneş Kitabevi, 2004:1256-68
15. Nisar PJ, Acheson AG, Neal KR, Scholefield JH. Stapled hemorrhoidopexy compared with conventional hemorrhoidectomy: systematic review of randomized, controlled trials. *Dis Colon Rectum* 2004;47(11):1837-45.
16. Palimento D, Picchio M, Attanasio U, Lombardi A, Bambini C, Renda A. Stapled and open hemorrhoidectomy: randomized controlled trial of early results. *World J Surg* 2003;27(2):203-7.
17. Oughriss M, Yver R, Faucheron JL. Complications of stapled hemorrhoidectomy: a French multicentric study. *Gastroenterol Clin Biol* 2005;29(4):429-33.
18. Papillon M, Arnaud JP, Descottes B, Gravie JF, Hutten X, De Manzini N. Treatment of hemorrhoids with the Longo technique. Preliminary results of a prospective study on 94 cases. *Chirurgie* 1999;124(6):666-9.
19. Orrom W, Hayashi A, Rusnak C, Kelly J. Initial experience with stapled anoplasty in the operative management of prolapsing hemorrhoids and mucosal rectal prolapse. *Am J Surg* 2002;183(85):519-24.
20. Cheetham MJ, Cohen CR, Kamm MA, Phillips RK. A randomized, controlled trial of diathermy hemorrhoidectomy vs. stapled hemorrhoidectomy in an intended day-care setting with longer-term follow-up. *Dis Colon Rectum* 2003;46(4):491-7.
21. Habr-Gama A, e Sous AH Jr, Roveló JM, et al. Stapled hemorrhoidectomy: initial experience of a Latin American group. *J Gastrointest Surg* 2003;7(6):809-13.
22. Hetzer FH, Demartines N, Handschin AE, Clavien PA. Stapled vs excision hemorrhoidectomy: long-term results of a prospective randomized trial. *Arch Surg* 2002;137(3):337-40.
23. Khalil KH, O'Bichere A, Sellu D. Randomized clinical trial of sutured versus stapled closed hemorrhoidectomy. *Br J Surg* 2000;87(10):1352-5.
24. Mehigan BJ, Monson JR, Hartley JE. Stapling procedure for haemorrhoids versus Milligan-Morgan haemorrhoidectomy: randomized controlled trial. *Lancet* 2000;355(9206):782-5.
25. Nahas SC, Borba MR, Brochado MCT, Marques CFS, Nahas CSR, Miott-Neto B. Stapled hemorrhoidectomy for the treatment of hemorrhoids. *Arq Gastroenterol* 2003;40(1):35-9.
26. Shalaby R, Desoky A. Randomized clinical trial of stapled versus Milligan-Morgan hemorrhoidectomy. *Br J Surg* 2001;88(8):1049-53.
27. Corman ML, Gravié JF, Hager T, et al. Stapled haemorrhoidopexy: a consensus position paper by an international working party - indications, contra-indications and technique. *Colorectal Dis* 2003;5(4):304-10.
28. Ho YH, Tsang C, Tang CL, Nyam D, Eu KW, Seow-Choen F. Anal sphincter injuries from stapling instruments introduced transanally: randomized, controlled study with endoanal ultrasound and anorectal manometry. *Dis Colon Rectum*. 2000;43(2):169-73.
29. Ortiz H, Marzo J, Armendariz P. Randomized clinical trial of stapled hemorrhoidopexy versus conventional diathermy hemorrhoidectomy. *Br J Surg* 2002;89(11):1376-81.
30. Molloy RG, Kingsmore D. Life threatening pelvic sepsis after stapled haemorrhoidectomy. *Lancet* 2000;355(9206):810.
31. Smith EF, Baker RP, Wilken BJ, Hartley JE, White TJ, Monson JR. Stapled versus excision haemorrhoidectomy: long-term follow-up of a randomised controlled trial. *Lancet* 2003;361(9367):1437-8.
32. Mattana C, Coco C, Manno A, et al. Stapled hemorrhoidopexy and Milligan Morgan hemorrhoidectomy in the cure of fourth-degree hemorrhoids: long-term evaluation and clinical results. *Dis Colon Rectum* 2007;50(11):1770-5.
33. Jayaraman S, Colquhoun PH, Malthaner RA. Stapled hemorrhoidopexy is associated with a higher long-term recurrence rate of internal hemorrhoids compared with conventional excisional hemorrhoid surgery. *Dis Colon Rectum* 2007;50(9):1297-305.