

# Laparoscopic Myomectomy

## Dr R K Mishra

Professor and Head of Minimal Access Surgery, TGO University, India  
First University Qualified Master Minimal Access Surgeon of India (M.MAS)  
Editor in Chief World Journal of Laparoscopic Surgery (WJOLS)  
Member World Association of Laparoscopic Surgeon (WALS)  
Member European Association for Endoscopic Surgery (EAES)  
Member European Association for Transluminal Surgery (EATS)  
Member Society of American Gastrointestinal and Endoscopic Surgeons (SAGES)  
Member Society of Laparoendoscopic Surgeons (SLS)  
Member Society of Robotic Surgery (SRS)  
Member Clinical Robotic Surgery Association (CRSA)  
Member Association of Surgeons of India (ASI)  
Member Indian Medical Association (IMA)  
President All India Specially Abled Association (AISAA)  
Member Indian Association of Gastrointestinal Endosurgeons (IAGES)  
Chairman, Delhi Laparoscopy Hospital, Pvt. Ltd. & Director, World Laparoscopy Hospital, Gurgaon

Fibroids are a common uterine tumor affecting 20 to 25 percent women. Fibroid develops from benign transformation of a single smooth muscle cell. The growth of myoma is dependent on many factors. Increased estrogen stimulation alone or together with growth hormone or human placental lactogen appears to be the major growth regulator of fibroid.

The severities of symptoms depend on the number of tumor, size and location. Many time they cause abdominal pressure so, urinary frequency, abdominal pain or constipation. One of the common finding is DUB due to altered blood flow through the uterus. The fibroid many time does not affect pregnancy.

In women with menorrhagia the hematocrit is used to asses the degree of anemia. Patients with large broad ligament fibroid may require an intravenous pyelogram to rule out any ureteral obstruction. For anemic patients preoperative treatment with gonadotropin releasing hormone may enable restoration of a normal hematocrit and decrease the size of myoma and thus reduce the risk of transfusion.

Intraoperatively use of dilute vasopressin helps to minimize the blood loss. Vertical uterine incision bleed less than transverse incision.

Single, vertical, anterior, midline incisions are least likely to form adhesion. Although sutures predispose to adhesions, they are often necessary to close the uterine defect.

If the endometrial cavity is entered due to large myoma a patient who subsequently becomes pregnant should undergo cesarean delivery.

Preoperative GnRH agonist has been used by some gynecologists to decrease myomas and intraoperative blood loss.

The risk of future uterine rupture is a major concern following myomectomy. The difficulty of adequately closing the layers laparoscopically and use of electro-coagulation may contribute to the risk of uterine rupture.

Uteroperitoneal fistulas may follow laparoscopic myomectomy because meticulous laparoscopic approximation of all layers is very difficult. Use of electrosurgery for hemostasis inside the uterine defect may also increase the risk of uteroperitoneal fistula formation.

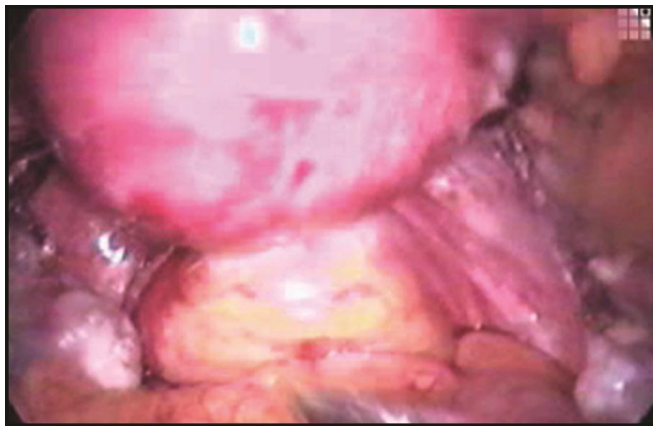
The chances of postoperative adhesion are also quite high in case of laparoscopic myomectomy. A single uterine incision for removal of multiple leiomyomas and subserosal approximation of the uterine defect should be done.

Laparoscopic assisted myomectomy can reduce the chance of this complication. The suturing will be done outside so decreasing the operating time and secure layered suturing ensures uterus does not rupture in later pregnancy. Pelvic observation during the laparoscopy allows the diagnosis and treatment of any other disease like endometriosis or adhesion. The criteria for LAM are myoma greater than 5 cm, numerous myomas, requiring vigorous use of morcellator, deep intramural myoma and removal that require uterine repair with sutures.

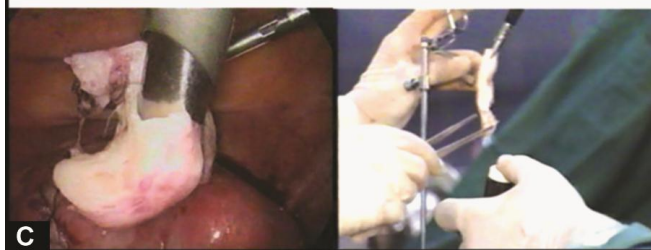
## Procedure

Pedunculated myomas are easiest to remove by just coagulating and cutting the stalk. Diluted vasopressin may be injected in the base of stalk.

Intramural fibroid require more manipulation so dilute vasopressin should be injected to multiple site between the myometrium and the fibroid capsule (Figs 35.1 to 35.2C). An vertical incision is made on the serosa overlying the leiomyomas using the monopolar electrode. The incision is extended until it reaches the capsule. The myometrium retracts as incision is made, exposing the tumor. Two grasping tooth forceps hold the edges of myometrium and the suction irrigator is used as blunt probe to remove covering of the leiomyomas from its capsule. The myoma crew should be inserted into the fibroid to apply traction while the suction irrigation instrument can be used as a blunt dissector. The CO<sub>2</sub> laser is used to further dissect capsular attachment. Vessels are electrocoagulated before being cut. After complete myoma removal the uterine defect is irrigated, bleeding points are identified and controlled with the open jaw of bipolar. If the fibroid is small and patient does not want baby, the edges of the uterine defects are approximated by coagulating the myometrium without suturing and tube ligation is performed. If the defect is deep situated, the edges of defect should be approximated by using 4-0 PDS. The repair mainly involve serosal and subserosal layer or can be in one layer. Sutures are applied at a distance of 5 mm. After repair, thorough suction and irrigation should be performed. Some gynecologist use adhesive medical glues over the suture line to prevent adhesion. Even in the hand of expert the laparoscopic myomectomy is difficult. Tumble square knot is better to use if the edges are in tension. Dundee jamming knot with continuous suturing may be used if there is not much tension followed by Aberdeen termination. Precise suturing of several layers is almost impossible laparoscopically.



**Fig. 35.1:** Colpotomy



**Figs 35.2A to C:** Morcellator is necessary equipment for myoma tissue retrieval

Intraligamentous and broad ligament fibroid are difficult to remove due to risk of injury to ureter and uterine artery at the time of dissection. Following a thorough exposure of ureter and vessels and depending on the location of myoma, an incision is made on the anterior or posterior leaf of the broad ligament and the leiomyomas is slowly shelled as other subserosal or intramural fibroid.

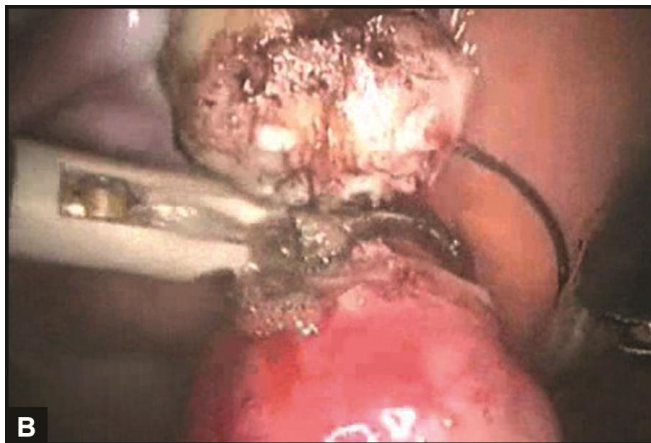
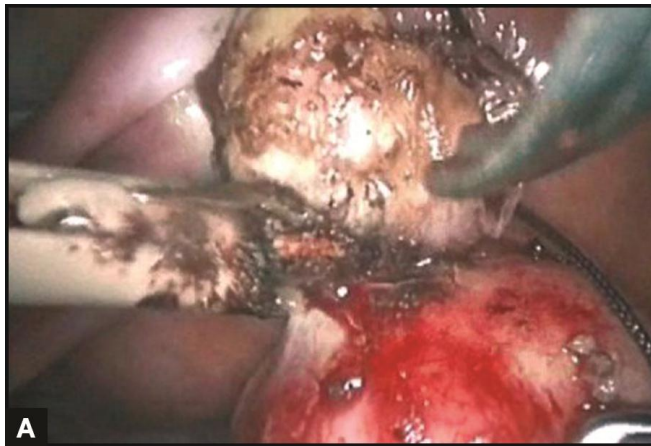
Throughout the procedure the location of the ureter is monitored, bleeding points are controlled by bipolar. The broad ligament and peritoneum are not closed in cases of broad ligament Myoma. If postoperative bleeding is suspected, a drain should be left.

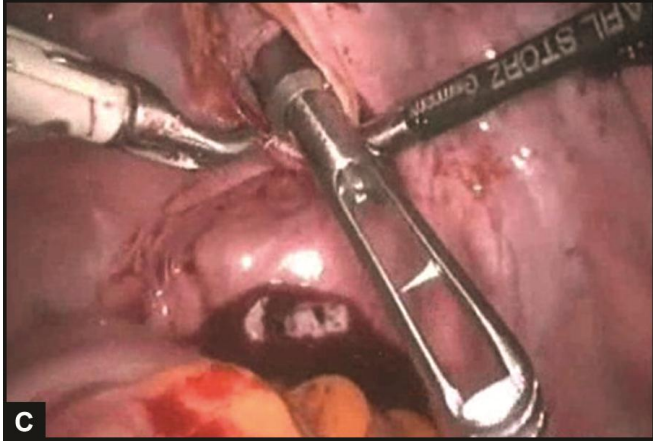
## Removal of Myoma

Fibroid removal is one of the difficult and time consuming procedures. Larger myoma may be removed through posterior colpotomy (Fig. 35.3C). In women with concurrent posterior cul-de-sac pathology posterior colpotomy is not safe. Medium and large size fibroid is morcellated using a morcellator (Figs 35.2A to 35.3C), scalpel (Figs 35.5A to D) or scissors. The process is ineffective for calcified myomas.

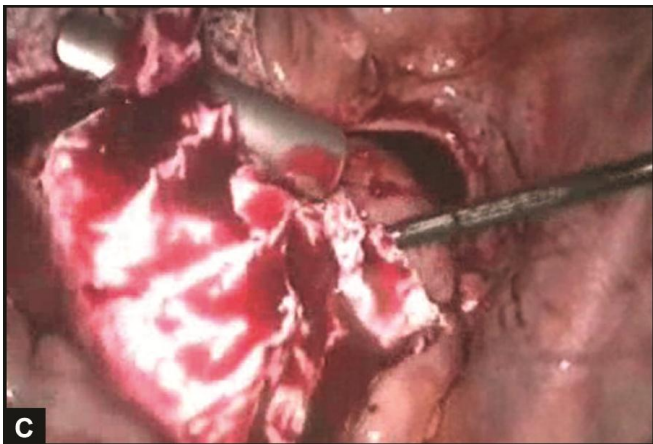
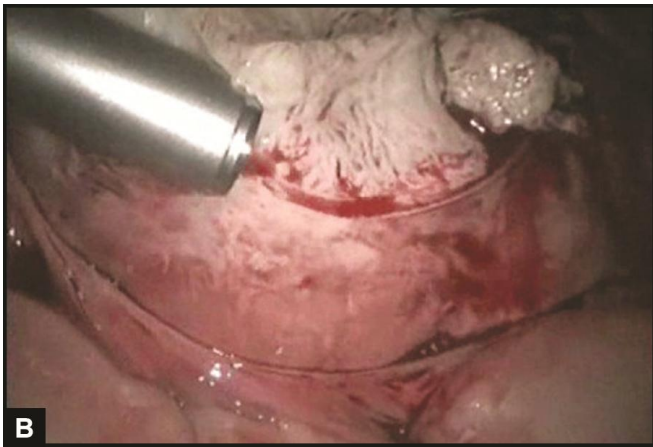
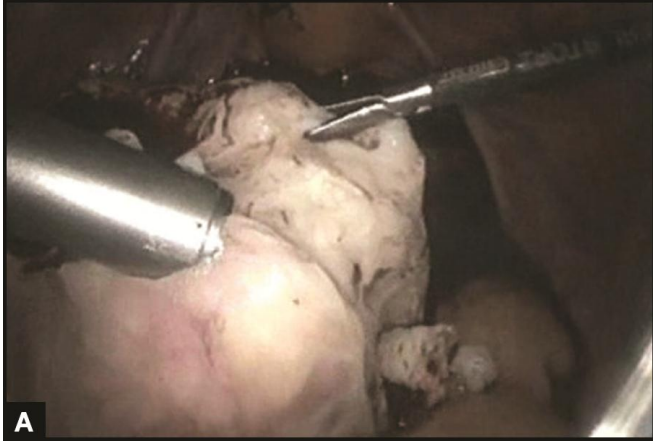
For infected tissue and in case of suspected carcinoma tissue retrieval bag should be used. Many sizes of disposable tissue retrieval bags are available and hard rim of these retrieval bags are easy to negotiate inside the abdominal cavity.

For large size gynecological tissue, colpotomy route is good for retrieval. Colpotomy can be done laparoscopically with the help of heel of hook. Counter pushing by other instruments is effective. Sponge over sponge holding forceps is inserted in posterior vaginal fornix by one assistant and surgeon cuts the vaginal fascia between both the uterosacral ligaments with the heel of hook.

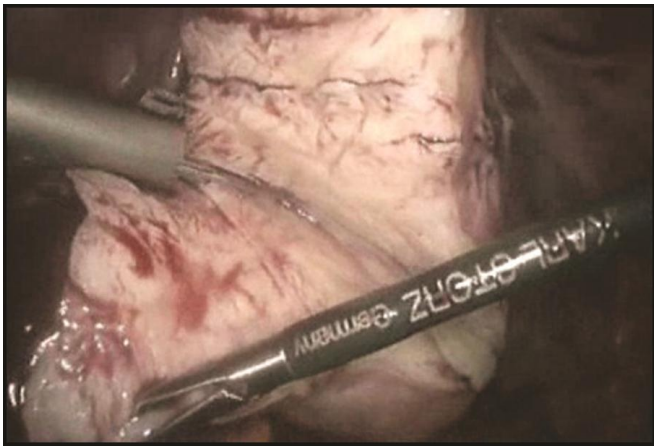
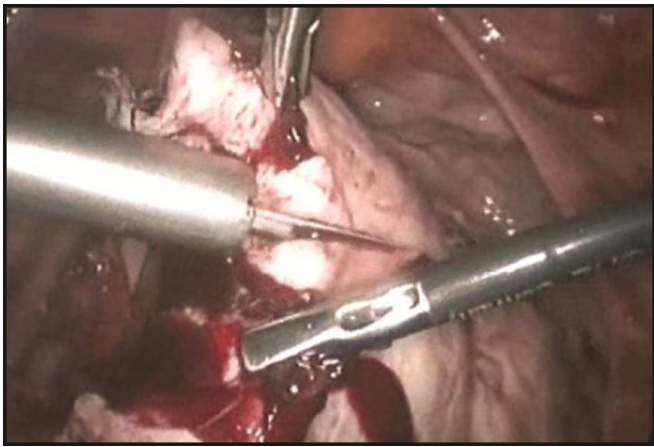
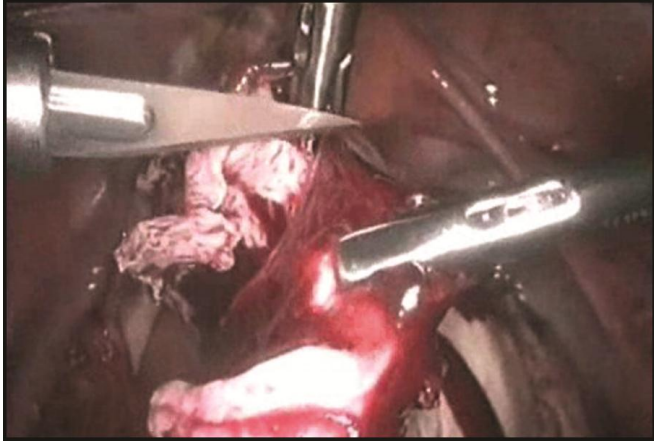


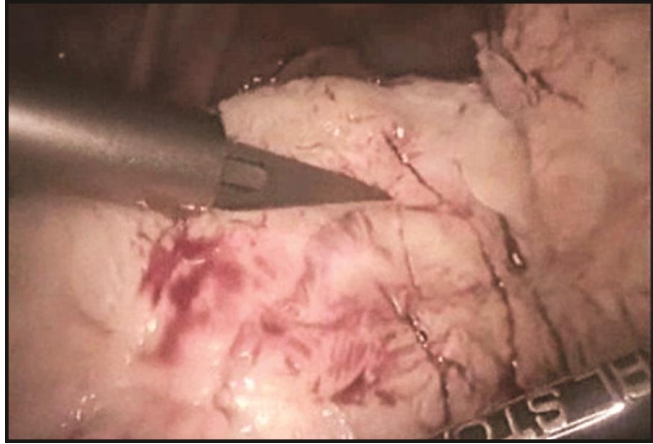


**Figs 35.3A to C:** Dissection of myoma



**Figs 35.4A to C:** Morcellation of myoma





**Figs 35.5 A to D:** Endoknife used to divide myoma

Use of morcellator is another way which facilitates grinding of solid tissue and then these can be taken out without any difficulty (Fig. 35.3). Recently many companies have launched battery operated morcellator. The morcellator is important instrument for tissue retrieval in myomectomy and splenectomy (Figs 35.4A to C).

## **BIBLIOGRAPHY**

1. Banas T, Klimek M, Fugiel A, Skotniczny K. Spontaneous uterine rupture at 35 weeks' gestation, 3 years after laparoscopic myomectomy, without signs of fetal distress. *J Obstet Gynaecol Res* 2005;31(6):527–30.
2. Banas T, Klimek M, Fugiel A, Skotniczny K. Spontaneous uterine rupture at 35 weeks' gestation, 3 years after laparoscopic myomectomy, without signs of fetal distress. *J Obstet Gynaecol Res* 2005;31(6):527–30.
3. Dubuisson J, Fauconnier A, Deffarges J, Norgaard C, Kreiker G, Chapron C. Pregnancy outcome and deliveries following laparoscopic myomectomy. *Hum Reprod* 2000b;15:869–73.
4. Dubuisson J, Fauconnier A, Deffarges J, Norgaard C, Kreiker G, Chapron C. Pregnancy outcome and deliveries following laparoscopic myomectomy. *Hum Reprod* 2000b;15:869–73.
5. Dubuisson JB, Fauconnier A, Chapron C, Kreiker G, Norgaard C. Reproductive outcome after laparoscopic myomectomy in infertile women. *J Reprod Med* 2000a; 45:23–30.
6. Dubuisson JB, Fauconnier A, Chapron C, Kreiker G, Norgaard C. Reproductive outcome after laparoscopic myomectomy in infertile women. *J Reprod Med* 2000a; 45:23–30.
7. Farmer RM, Kirschbaum T, Potter D, Strong TH, Medearis AL. Uterine rupture during trial of labour after previous cesarean section. *Am J Obstet Gynecol* 1991;65:996–1001.
8. Farmer RM, Kirschbaum T, Potter D, Strong TH, Medearis AL. Uterine rupture during trial of labour after previous cesarean section. *Am J Obstet Gynecol* 1991;65:996–1001.
9. Flamm BL, Goings JR, Liu Y, Wolde-Tsadik G. Elective repeat cesarean delivery versus trial of labor: a prospective multicenter study. *Obstet Gynecol* 1994;83:927–32.
10. Flamm BL, Goings JR, Liu Y, Wolde-Tsadik G. Elective repeat cesarean delivery versus trial of labor: a prospective multicenter study. *Obstet Gynecol* 1994;83:927–32.
11. Golan D, Aharoni A, Gonen R, Boss Y, Sharf M. Early spontaneous rupture of the post myomectomy gravid uterus. *Int J Gynaecol Obstet* 1990;31(2):167–70.
12. Golan D, Aharoni A, Gonen R, Boss Y, Sharf M. Early spontaneous rupture of the post myomectomy gravid uterus. *Int J Gynaecol Obstet* 1990;31(2):167–70.
13. Grande N, Catalano GF, Ferrari S, Marana R. Spontaneous uterine rupture at 27 weeks of pregnancy after laparoscopic myomectomy. *J Minim Invasive Gynecol* 2005;12:301.
14. Grande N, Catalano GF, Ferrari S, Marana R. Spontaneous uterine rupture at 27 weeks of pregnancy after laparoscopic myomectomy. *J Minim Invasive Gynecol* 2005;12:301.
15. Hurst BS, Matthews ML, Marshburn PB. Laparoscopic myomectomy for symptomatic uterine myomas. *Fertil Steril* 2005;83:1–23.
16. Hurst BS, Matthews ML, Marshburn PB. Laparoscopic myomectomy for symptomatic uterine myomas. *Fertil Steril* 2005;83:1–23.
17. Kumakiri J, Takeuchi H, Kitade M, Kikuchi I, Shimanuki H, Itoh S, Kinoshita K. Pregnancy and delivery after laparoscopic myomectomy. *J Minim Invasive Gynecol* 2005;12:241–6.

18. Kumakiri J, Takeuchi H, Kitade M, Kikuchi I, Shimanuki H, Itoh S, Kinoshita K. Pregnancy and delivery after laparoscopic myomectomy. *J Minim Invasive Gynecol* 2005;12:241–6.
19. Landi S, Fiaccavento A, Zaccoletti R, Barbieri F, Syed R, Minelli L. Pregnancy outcomes and deliveries after laparoscopic myomectomy. *J Am Assoc Gynecol Laparosc* 2003;10:177–81.
20. Landi S, Fiaccavento A, Zaccoletti R, Barbieri F, Syed R, Minelli L. Pregnancy outcomes and deliveries after laparoscopic myomectomy. *J Am Assoc Gynecol Laparosc* 2003;10:177–81.
21. Lieng M, Istre O, Langebrekke A. Uterine rupture after laparoscopic myomectomy. *J Am Assoc Gynecol Laparosc* 2004;11:92–3.
22. Lieng M, Istre O, Langebrekke A. Uterine rupture after laparoscopic myomectomy. *J Am Assoc Gynecol Laparosc* 2004;11:92–3.
23. Nielsen TF, Ljungblad U, Hagberg H. Rupture and dehiscence of cesarean section during pregnancy and delivery. *Am J Obstet Gynecol* 1989;160:569–73.
24. Nielsen TF, Ljungblad U, Hagberg H. Rupture and dehiscence of cesarean section during pregnancy and delivery. *Am J Obstet Gynecol* 1989;160:569–73.
25. Nkemayim DC, Hammadeh ME, Hippach M, Mink D, Schmidt W. Uterine rupture in pregnancy subsequent to previous laparoscopic electromyolysis. Case report and review of the literature. *Arch Gynecol Obstet* 2000;264:154–6.
26. Nkemayim DC, Hammadeh ME, Hippach M, Mink D, Schmidt W. Uterine rupture in pregnancy subsequent to previous laparoscopic electromyolysis. Case report and review of the literature. *Arch Gynecol Obstet* 2000;264:154–6.
27. Ozeren M, Ulusov M, Uvanik E. First-trimester spontaneous uterine rupture after traditional myomectomy: case report. *Isr J Med Sci* 1997;33(11):752–3.
28. Ozeren M, Ulusov M, Uvanik E. First-trimester spontaneous uterine rupture after traditional myomectomy: case report. *Isr J Med Sci* 1997;33(11):752–3.
29. Pelosi MA III, Pelosi MA. Spontaneous uterine rupture at thirtythree weeks subsequent to previous superficial laparoscopic myomectomy. *Am J Obstet Gynecol* 1997;177:1547–9.
30. Pelosi MA III, Pelosi MA. Spontaneous uterine rupture at thirtythree weeks subsequent to previous superficial laparoscopic myomectomy. *Am J Obstet Gynecol* 1997;177:1547–9.
31. Phelan JP, Clark SL, Diaz F, Paul RH. Vaginal birth after cesarean. *Am J Obstet Gynecol* 1987;157:1510–15.
32. Phelan JP, Clark SL, Diaz F, Paul RH. Vaginal birth after cesarean. *Am J Obstet Gynecol* 1987;157:1510–15.
33. Pisarska MD, Carson SA. Incidence and risk factors for ectopic pregnancy. *Clin Obstet Gynecol* 1999;42:2–8.
34. Pisarska MD, Carson SA. Incidence and risk factors for ectopic pregnancy. *Clin Obstet Gynecol* 1999;42:2–8.
35. Roopnarinesingh S, Suratsingh J, Roopnarinesingh A. The obstetric outcome of patients with previous myomectomy or hysterotomy. *West Indian Med J* 1985;34:59–62.
36. Roopnarinesingh S, Suratsingh J, Roopnarinesingh A. The obstetric outcome of patients with previous myomectomy or hysterotomy. *West Indian Med J* 1985;34:59–62.
37. Seiner P, Farina C, Todros T. Laparoscopic myomectomy and subsequent pregnancy: results in 54 patients. *Hum Reprod* 2000;15:1993–6.
38. Seiner P, Farina C, Todros T. Laparoscopic myomectomy and subsequent pregnancy: results in 54 patients. *Hum Reprod* 2000;15:1993–6.
39. Stringer NH, Strassner HT, Lawson L, Oldham L, Estes C, Edwards M and Stringer EA. Pregnancy outcomes after laparoscopic myomectomy with ultrasonic energy and laparoscopic suturing of the endometrial cavity. *J Am Assoc Gynecol Laparosc* 2001;8:129–36.
40. Stringer NH, Strassner HT, Lawson L, Oldham L, Estes C, Edwards M, Stringer EA. Pregnancy outcomes after laparoscopic myomectomy with ultrasonic energy and laparoscopic suturing of the endometrial cavity. *J Am Assoc Gynecol Laparosc* 2001;8:129–36.