

# ROUTINE VERSUS SELECTIVE INTRA-OPERATIVE CHOLANGIOGRAPHY DURING LAPAROSCOPIC CHOLECYSTECTOMY

Ghazalah Bassam A.

## Abstract

### Background:

Undergoing Intraoperative cholangiography during laparoscopic cholecystectomy reveals the anatomy of the biliary tree and stones contained within it. The use of intraoperative cholangiography may be routine for all laparoscopic cholecystectomy. An alternative approach is a selective policy, performing intraoperative cholangiography only for those cases in which choledocholithiasis is suspected on clinical grounds, or those for which the anatomy appears unclear at operation. The literature pertaining to both approaches is reviewed, to delineate their respective merits.

Method: Relevant articles were reviewed from the Medline database.

Results: The literature reviewed consisted of retrospective analyses. Overall it seems that the incidence of unsuspected retained stones was 4-5%, but only 15% of these would go on to cause clinical problems. The literature shows that the incidence of complete transection of the common bile duct was rare for both routine and selective intraoperative cholangiography policies, and did not differ between them. Rates of minor bile duct injury did not differ between groups, but was more likely to be recognized in the routine group than the selective ( $P = 0.01$ ).

Conclusion: Routine intraoperative cholangiography yields a very little useful clinical information over and above that which is obtained from selective policies. Large numbers of unjustified intraoperative cholangiography are performed routinely, and therefore a selective policy is advised to be followed.

**Keywords:** Cholangiogram, selective cholangiogram, bile ducts injury, choledocholithiasis.

### Introduction:

Opinion is divided whether intra-operative cholangiography should be performed routinely or on a selective basis during laparoscopic cholecystectomy

The rationale for performing intraoperative cholangiography (IOC) during traditional open cholecystectomy has undergone several revisions since it was first described by Mirizzi [1] in 1931 to assess the presence of unsuspected bile duct pathology or abnormal anatomy.

Since the introduction of laparoscopic cholecystectomy (LC) in the late 1980s, which has become the gold standard in the management of gallstone disease [2], there has been considerable controversy regarding the proper role of IOC for patients

undergoing LC as bile duct injury (BDI) seems to be more frequent in LC at least during the learning period of the laparoscopic techniques.

One of the problems that continues to generate controversy among laparoscopic surgeons concerns intraoperative cholangiography (I.O.C.). Should it be performed routinely, selectively or perhaps not at all?

The main reason to the ongoing controversy is the overall very low rate of bile duct complications after LC, estimated between 0.1 to 0.5% (significantly superior to OC). This low rate renders prospective, randomised trials very difficult, as it is necessary to include a high (over 1,000 in each group) number of patients to achieve statistically significant results.

The protagonists in favour of routine intra-operative imaging of the bile ducts have 3 arguments [9,10]. First, by clarifying the anatomy of the extrahepatic and possibly aberrant bile ducts, injuries should be prevented; and if perchance they have already occurred, they should be discovered immediately so reducing or preventing the possible early and late outcomes.

Second, "unexpected", silent stones in the ducts will be detected and can then be dealt with. Third, the routine use of I.O.C. provides the practice required to perform this investigation expeditely if required.

The indications for selective intraoperative cholangiography (IOC) include a clinical history of jaundice, pancreatitis, elevated bilirubin level, abnormal liver function test results, increased amylase levels, a high lipase level, or dilated common bile duct on preoperative ultrasonography. Although these clinical features are widely accepted as indications for IOC, they have not been tested for their ability to predict choledocholithiasis.

Preoperative identification of a dilated common bile duct >9mm or elevated bilirubin levels or clinical jaundice during cholecystectomy can be the sole criteria for performing IOC on a selective basis in patients without malignancy.

Reliance on a history of remote jaundice, pancreatitis, elevated liver function test values, or pancreatic enzymes results in unnecessary IOCs. ( J GASTROINTEST SURG 2005;9:1371–1377) \_ 2005 The Society for Surgery of the Alimentary Tract.

Those who practice I.O.C. selectively counter with the following 4 statements [5,6]. First, I.O.C. cannot be performed for technical reasons in 5% to 9% of patients, even in experienced hands. Second, I.O.C. is no guarantee against bile duct injury, as witness the reports by protagonists of the investigation. It is only one of several steps in avoiding this calamity and it cannot replace the meticulous dissection of Callot's triangle. In fact, injuries have been caused (albeit rarely) by the cholangiography catheter itself [7]. Third, false-positive and false negative findings during I.O.C. only confirm the old axiom that there are no 100% fool-proof methods for detecting common duct stones [8]. Fourth, the (uncertain) advantages of I.O.C. have to be weighed against the increase in operating time and

cost.

### **Materials and methods:**

A review article (Met analysis) of the published reports and articles was done to compare between the routine versus the selective use of intraoperative cholangiograms during laparoscopic cholecystectomy was performed by collecting these articles from the Medline literatures and resources through the websites (springerlink,high wire press, google and many others ) and the data was summarized and presented in that report.

### **Results:**

The articles reviewed consisted of retrospective analyses. The Overall incidence of unsuspected retained stones was 4%, but only 15% of these would cause clinical problems. It was found that the incidence of complete transection of the common bile duct was rare for both routine and selective intraoperative cholangiography policies, and did not differ between them. The rates of minor bile duct injury shows no difference between groups, but was more likely to be recognized in the routine group than the selective ( $P = 0.01$ ).

1-A study done by Nathaniel J. Soper, M.D. and Deanna L. Dunnegan, R.N. Department of Surgery, Washington University School of Medicine, St. Louis, Missouri, U.S.A. from April 1991 to February 1992, 164 consecutive patients underwent laparoscopic cholecystectomy , of whom 49 (30%) patients were excluded from the trial due to indications for or against cholangiography. In the remaining 115 (70%) patients, 56 were randomized to the cholangiography group while 59 patients did not receive cholangiograms. Duration of postoperative Hospitalization and interval to return to full activity were identical in The two groups. Static cholangiograms added 16 +/- 1 min (mean ± SEM) To the procedures ( $p < 0.01$ ). Cholangiography increased the total charges For the operation by almost \$700 ( $p < 0.01$ ). Cholangiograms were Performed successfully in 94.6% of the patients and changed the operative Management in 4 (7.5%) patients. In the 2 patients demonstrating cystic duct stones, the calculi were removed laparoscopically. In the 2 individuals whose gallbladders filled with contrast material, great care was taken during dissection of the gallbladder from its bed. In one of these patients an aberrant tubular structure was identified entering the posterior aspect of the gallbladder fundus, which was Clipped and divided. Both of these patients had closed suction drainage catheters placed into the right upper quadrant, there was no bile in the drain output and the drains were removed on the first postoperative day without sequelae.

There was 1 (1.9%) false negative study. Intra-operative cholangiography did not reveal aberrant bile ducts at risk of injury from the operative dissection. There was no mortality or cholangiogram-related morbidity in either group. In follow-up ranging from 2-12 months, there has been no clinical evidence of bile duct injury or retained common bile duct stones.

**2-**A study done by Shih-Chi Wu, MD et. al from the division of Trauma, Changhua Christian Hospital, Changhua, Taiwan on 244 (98%) patients underwent LC and 5 (2%) patients were converted to open cholecystectomy between may 1998 and January 2000, Intraoperative cholangiogram (IOC) was only performed in patients who fulfilled predetermined criteria of clinical jaundice ,CBD more than 9 mm and preoperative ultrasound and abnormal liver profile . Among 90 patients who had IOC, only 23 patients had CBD stones that were removed either by transcystic duct stone extraction (61%) or CBD exploration (39%). The additional procedures to remove CBD stone did not prolong the hospitalization. There were four wound infections and one cystic stump leakage. Only one patient presented with clinical jaundice 36 months after the cholecystectomy and subsequent ERCP removed a CBD stone. This patient fulfilled the criteria for IOC however; the procedure was unsuccessful due to the occluded cystic duct.

**3-**A study done by Jeffrey S. Barkun, M.D. et. al from the Divisions of General Surgery and Gastroenterology, McGill University, Montreal, Quebec, Canada from may 1990 to feb.1992 on the first 1300 patients undergoing LC at McGill University. Preoperative indications for ERCP were recorded, radiological findings were standardized, and technical points for a safe LC were emphasized. A total of 106 patients underwent 127 preoperative ERCPs. Fifty patients were found to have choledocholithiasis (3.8%), and clearance of the common bile duct (CBD) with endoscopic sphincterotomy was achieved in 45 patients. The other five patients underwent open cholecystectomy with common duct exploration. Intraoperative cholangiography (IOC) was attempted in only 54 patients (4.2%), 6 of whom demonstrated choledocholithiasis. Forty-nine postoperative ERCPs were performed in 33 patients and stones were detected in 17 (1.3%), with a median follow-up time of 22 months. Endoscopic duct clearance was successful in all of these. The incidence of CBD injury was 0.38%, and a policy of routine operative cholangiography Might only have led to earlier recognition of duct injury in one case. The rate of complication for all ERCPs was 9% and the associated median duration of the hospital stay was 4 days. The median duration of the hospital stay after open CBD exploration was 13 days. In only one case could routine IOC have possibly resulted in earlier recognition and different management of the injury.

**4-**A retrospective study done by A. Nickkholgh et. al in the Department of General and Laparoscopic Surgery, Arad General Hospital, Tehran 15618, Iran titled Routine versus selective intraoperative cholangiography during laparoscopic cholecystectomy Published in the surgical endoscopy 12 may 2006 data from hospital records, operative notes, cholangiographic studies, and follow-up of 2130 patients who underwent LC from January 1992 to February 2001 were gathered and analyzed and the results are shown in table 1.

**Table 1: Statistical analysis, RIOC vs SIOC****Table 4.** Statistical analysis, RIOC vs SIOC

	SIOC	RIOC	<i>p</i> value
No. of cases	159/800	1,133/1,330	
Success rate (%)	88.6	90.9	0.015 <sup>a</sup>
Incidence of ductal stones	9 (1.1%)	37 (3.3%)	< 0.01 <sup>a</sup>
Inability to detect stones <sup>b</sup>	9/18 (50%)	2/39 (5%)	< 0.01 <sup>a</sup>
Sensitivity (%)	50	97.4	< 0.01 <sup>a</sup>
Specificity (%)	100	100	
Negative predictive value (%)	98.6	99.8	< 0.01 <sup>a</sup>
Positive predictive value (%)	100	100	

RIOC, routine intraoperative cholangiography; SIOC, selective intraoperative cholangiography

<sup>a</sup> Statistically significant ( $p < 0.05$ )

<sup>b</sup> Ratio of false-negative cases to all documented ductal stones during follow-up in each approach

**5-A** study done by David R. Flum, MD; et. al From the Department of Surgery, University of Washington, Seattle, titled Common Bile Duct Injury During Laparoscopic Cholecystectomy and the Use of Intraoperative Cholangiography. Adverse Outcome or Preventable Error?

30630 LCs and 76 major CBD injuries (2.5/1000 operations) were identified in this analysis. There were no significant differences between injured and non injured patients in demographics, disease, payer status, or hospital variables. A CBD injury occurred in 3.2 of 1000 LCs in the early case order of surgeons compared with 1.7 per 1000 at later points ( $P=.01$ ) (relative risk, 1.81; 95% confidence interval, 1.44-2.88). The rate of injury in LCs performed without IOC was 3.3 per 1000 compared with 2.0 per 1000 in LCs with IOC ( $P=.02$ ) (relative risk, 1.7; 95% confidence interval, 1.1-2.6). Surgeon's experience and IOC use were independent predictors of injury.

### Discussion:

After Dr. Mirizzi first performed operative cholangiography in 1931, the application of operative cholangiography for the evaluation of choledocholithiasis has become more important especially in the era of laparoscopic cholecystectomy.

There are debates and lack of consensus in the routine or selective use of IOC.

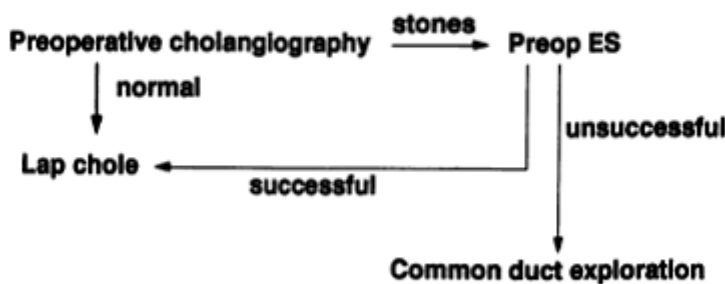
The rationale for performing cholangiography routinely during laparoscopic cholecystectomy is to prevent injury to the main biliary tree, to detect anomalies

which may change the operative strategy, and to document the presence or absence of common bile duct stones. We feel that cholangiography is only one component of the operative strategy to prevent bile duct injuries during laparoscopic cholecystectomy.

The most critical technical maneuver during laparoscopic cholecystectomy is to dissect the infundibulum of the gallbladder from both the

ventral and dorsal aspects of Calot's triangle and thereby demonstrate the cystic duct arising in continuity from the gallbladder neck [7]. Although previous studies of bile duct injuries following open cholecystectomy suggested duct injury to occur much more frequently when cholangiograms were not performed [12], the data from the current randomized study as well as results published previously from our institution [11] and those of other surgeons [13] support the concept that it is possible to perform laparoscopic cholecystectomy safely when cholangiogram are not done routinely.

### Probable Common Duct Stones



**Figure 1.** Algorithm for detection and management of CBD stones. ES: endoscopic sphincterotomy.

**Table 2. CBD STONES AND INJURIES**

Series	No. of Patients/ Follow-up (mo)	IOC (%)	CBD Injury (%)	Retained Stones (%)	Total Stones (%)
Flowers et al. <sup>3</sup>	384/3-15	45	0.3	1.4	4.7
Clair et al. <sup>17</sup>	514/NA	7	0.2	0.8	2.1
Lillemoe et al. <sup>19</sup>	400/NA	2	0	0.75	4.25
Soper and Dunnegan <sup>28</sup>	415/1-22	34	0.2	0.2	4.1
Sackier et al. <sup>4</sup>	516/NA	90	NA	NA	7 (+)
Current series	1300/13-34	4.2	0.38	1.3	5.6

NA: not applicable.

If we follow and abide the results of the routine IOC, it is likely that the rate of unnecessary conversion or postoperative interventional procedures (e.g., endoscopic sphincterotomy) could be unacceptably high. Furthermore, the extra-hepatic duct injury can occur even in the skilled hand of laparoscopic surgeons who advocate the routine use of IOC(14) Thus, the routine use of IOC does not provide insurance for avoiding extra-hepatic duct injury.

The other primary argument for performing cholangiography is to discover unsuspected choledocholithiasis and minimize the incidence of retained common bile duct stones.

Using selective cholangiogram approach, it have previously reported an incidence of retained common bile duct stones of 0.2% [ 11].

We assume that this low incidence of Choledocholithiasis and retained common bile duct stones stem from the liberal use of selective cholangiograms, as well as the referral pattern with many patients receiving pre-operative ERCP for suspected common bile duct stones.

Whether or not surgeons choose to perform cholangiography on a routine or selective basis during laparoscopic cholecystectomy, they must develop the technical facility to do so when needed [15]. Therefore, it is imperative to learn a number of different techniques for cystic duct cannulation and perfect these maneuvers early in one's operative experience to master the techniques.

Based on the practical experience of surgeons and theoretical considerations, we believe additional dissection of the cystic duct should be performed in patients who do not undergo operative cholangiography.

It is important to dissect a longer segment of the cystic duct in an attempt to visualize its junction with the common bile duct and to open and "milk" the cystic duct gently to discover and remove unsuspected cystic duct stones.

It is demonstrated that it took an average of 24 min to perform laparoscopic operative cholangiography. The mean difference in operative time between patients who underwent cholangiography and those who did not, however, was only 16 min. We assume that the unaccounted operating time in cases without cholangiography was spent performing this additional cystic duct dissection.

As stated above, surgeons performing laparoscopic cholecystectomy must dissect the neck of the gallbladder and cystic duct meticulously. Patients may require cholangiography on the basis of pre-operative investigations or due to intra-operative findings. These latter criteria include a dilated cystic duct >4 mm, the presence of cystic duct stones, and most importantly, unclear anatomy in the region of the porta hepatis. An additional benefit of gaining operative experience in this area is the ability to progress technically towards trans-cystic duct extraction of unsuspected common bile duct stones [16,18,20], techniques which require manual dexterity and the desire to discover such stones intra-operatively.

So we concludes that routine intraoperative cholangiogram yields a very little useful clinical information compared to the selective use of that technique with careful patient selection according to certain criteria, as long as meticulous operative dissection techniques are utilized.

technical ability to perform cholangiography must be developed by each surgeon early in his experience and applied when needed. Routine IOC in LC does not avoid all bile duct injury and it is not the main factor in reducing these injuries and meticulous dissection of callot's triangle and clearing the anatomy of the area before any clipping is the main factor but the selective use of IOC allows their early recognition and earlier correction with better short and long term outcomes and therefore lesser morbidity and mortality.

## References:

1. Mirizzi PL (1955) Calculi of the common bile duct (520 cases under the control of surgical cholangiography). *Mem Acad Chir (Paris)* 81: 834–841
2. NIH Consensus Development Panel on Gallstones, Laparoscopic Cholecystectomy (1993) Gallstones and laparoscopic cholecystectomy. *Surg Endosc* 7: 271–279
3. Flowers JL, Zucker KA, Graham SM, et al. Laparoscopic cholangiography: results and indications. *Ann Surg* 1992; 215:209-216.
4. Sackier JM, Berci G, Phillips E, et al. The role of cholangiography in laparoscopic cholecystectomy. *Arch Surg* 1991; 126:1021-1026.
5. Cuschieri, A., Dubois, F., Mouiel, J., Mouret, P., Becker, H., Buess, G., Trede, M., Troidl, H.: The European experience with laparoscopic cholecystectomy. *Am. J. Surg.* 161:385, 1991
6. Gillams, A., Cheslyn-Curtis, S., Russell, R.C.G., Lees, W.R.: Can cholangiography be safely abandoned in laparoscopic cholecystectomy? *Ann. R. Coll. Surg. Engl.* 74:248, 1992
7. Soper, N.J.: Laparoscopic cholecystectomy. *Curt. ProN. Surg.* 28:585, 1991
8. Gregg, R.O.: The case for selective cholangiography. *Am. J. Surg.* 155:540, 1988
9. Berci, G., Sakier, J.M., Paz-Partlow, M.: Routine or selected intraoperative cholangiography during laparoscopic cholecystectomy? *Am. J. Surg.* 161:355, 1991
- 10 Hunter, J.G.: Avoidance of bile duct injury during laparoscopic cholecystectomy. *Am. J. Surg.* 162:71, 1991
11. Soper, N.J., Stockmann, P.T., Dunnegan, D.L., Ashley, S.W.: Laparoscopic cholecystectomy: The new "gold standard"? *Arch. Surg.* 127:917, 1992.
12. Moossa, A.R., Mayer, A.D., Stabile, B.: Iatrogenic injury to the bile duct. *Arch. Surg.* 125:1028, 1990
13. Voyles, C.R., Petro, A.B., Meena, A.L., Haick, A.J., Koury, A.M.: A practical approach to laparoscopic cholecystectomy. *Am. J. Surg.* 161:365, 1991
14. Vezakis A, Davides D, Ammori BJ, et al. Intraoperative cholangiography during laparoscopic cholecystectomy. *Surg. Endosc.* 2000;14:1118–22
15. Way, L.W.: Bile duct injury during laparoscopic cholecystectomy (editorial). *Ann. Surg.* 215:195, 1992
16. Petelin, J.B.: Laparoscopic approach to bile duct pathology. *Surg. Laparosc. Endosc.* 1:33, 1991
17. Clair DG, Carr-Locke DL, Becker JM, Brooks DC. Routine cholangiography is not warranted during laparoscopic cholecystectomy (abstract). Presented at the 73rd Meeting of the New England Surgical Society, Balsams Dixville Notch, New Hampshire, September 27, 1992

18. Hunter, J.G.: Laparoscopic transcystic common bile duct exploration. Am. J. Surg. •63:53, 1992
19. Lillemoe KD, Yeo CJ, Talamini MA, et al. Selective cholangiography: current role in laparoscopic cholecystectomy. Ann Surg 1992; 215:269-276
20. Hunter, J.G., Soper, N.J.: Laparoscopic management of common bile duct stones. Surg. Clin. North Am. (*in press*).
21. Soper, Dunnegan, R.N.: Routine versus selective intraoperative cholangiogram during laparoscopic cholecystectomy. World Journal of surgery. 16, 1133-1140, 1992.
22. Matthew S. Metcalfe et. al: Is laparoscopic intraoperative cholangiogram a matter of routine? The American journal of surgery, Volume 190, Issue 4, 653, October 2005.
23. O. Detry et. al: The role of Intraoperative cholangiography in detecting and preventing bile duct injury during laparoscopic cholecystectomy. Acta chir belg, 2003, 103, 161-162.
24. Shih-Chi Wu, et. al: Selective intraoperative cholangiography and single stage management of common bile duct stone in Laparoscopic cholecystectomy. World J Surg (2005) 29, 1402-1408.
25. Jeffrey S. Barkun, et. al: Cholecystectomy without operative cholangiography, Annals of surgery Vol. 218, No. 3, 371-379.
26. A. Nickkholgh, S. Soltaniyekta, H. Kalbasi: Routine versus selective intraoperative cholangiography during laparoscopic cholecystectomy, Surg Endosc (2006) 20: 868-874.
27. David R. Flum, et. al: Common bile duct injury during laparoscopic cholecystectomy and the use of intraoperative cholangiography, Arch Surg. Nov. 2001, Vol 136, 1287-1292.
28. Soper NJ, Dunnegan DL. Laparoscopic cholecystectomy: experience of a single surgeon. World J Surg 1993; 17:16-20.

For more information please log on to <http://www.laparoscopyhospital.com>