

Review Study of Common Bileduct Injuries during Laparoscopic Cholecystectomy

Dr. J.K. Singh MS (General Surgeon)

Abstract

Iatrogenic common bileduct injuries are the worst complication of laparoscopic Cholecystectomy. The goal of this study is to increase awareness of the problem and educate surgeons about the consequences and proper management of these injuries

Material and Method

We analyzed review study of many multi center studies about common Bileduct injuries in Laparoscopic Cholecystectomy. A literature research performed using Internet.

Discussion

After introduction of laparoscopy Cholecystectomy in late decade of 1980, the field of general surgery was revolutionized, after the sudden the many articles about laparoscopic Cholecystectomy and bileduct injuries. It was found that laparoscopic has many benefits to patients' life less pain, less blood loss during operation decrease hospital stay, earlier return to normal activities and cosmeis. Inspite of these benefits unfortunately the data of many studies shows a higher incident of C.B.D injuries when compared with open Cholecystectomy at least .4- to .5 %verses .1 to .2% respectively. After review many articles about C.B.D injuries regarding risk factor of injuries their proper management and long term detrimental effect of bile duct injury on health and quality of life. It is still a gold standard for treatment of symptomatic gallstone disease, uncomplicated gall bladder diseases like mucocele, empyma, cholesterosis, porcelain GB, Adenomatous polyp of GB.

Conclusion:

After taking care of possibilities of CBD injury, there early diagnosis and proper management, laparoscopic Cholecystectomy safely chosen for patients to be proposed was surgican treatment and gold standard for GB stone diseases.

Introduction

Cholecystectomy is the most common gastro intestinal operation performs. Laparoscopic Cholecystectomy first performed by Erich Muhe in 1985 in Germany. In 1987 laparoscopically complete removed of GB was performed by Mourat in Lyon, France. After that introduction of laparoscopically Cholecystectomy into general practice in 1990, it has become the dominant procedure of GB surgery. The widespread acceptance of laparoscopic Cholecystectomy was base on anticipated reduction in post operative pain minimal injuries to tissue low intraoperative, Postoperative complication other CBD injuries, early return to work, now become a goal standard of treatment for GB stone in experience and safe hand.

Many articles source that soon after introduction, how every it became clear that laparoscopic Cholecystectomy was associated with unique complication compared with open Cholecystectomy, the CBD injuries higher, Highest rate were reported in early 1990s laparoscopic Cholecystectomy was introduced, suggesting a learning curve effect. In review by Strasburg et al and Roslyl et al. The incident of billiary injuries during open Cholecystectomy was found .2-.3%.

The review by Strasburg et al in 1995 of more than 124000 laparoscopic Cholecystectomy reported in literature found the incident of major bilduct injuries to .5%
As the surgeon passed through learning curved have reached “steady-state” and there has been no significant of improvement of incident of billiary duct injuries. The impact of major CBD injury is staggering to both the patient and health care system.

Article study shows that about 95% bile injuries are minor and were irrelevant to patients out come and only 5% were major and almost always requires a technologically demanding, expensive operative reconstruction of billiary tree. Inspect of proper diagnosis and treatment of major bile duct injuries fatality were found to 10-12%

As noted by WHO in 1947 health is not limited to absence of disease, fulfill of physical, mental, and social wellbeing, therefore the extent to which a procedure and disease process impact the physical, psychologics and social aspect of patient life and filling of wellbeing. Therefore to truly access a patient out come after CBD injury one most not measure the usual objective clinical outcome, but also evaluate the patients subjective health related quality of life.
In most of study it was found health related quality of life and time to returned to work among the patients who had CBD injuries during laparoscopic Cholecystectomy and under went treatment at secondary and tertiary center, out comes were compared with those under went uncomplicated laparoscopic Cholecystectomy

Material and Method

A literature search was performed using Google, Yahoo, Springer link, High wire press, the following search term were used. Iatrogenic bile duct injuries, common bilduct injuries during laparoscopic Cholecystectomy, post Cholecystectomy complication, long term detrimental effect of bilduct injuries. The 15 no of quality citations reviewed were selected for these reviews. The criteria for selection was

- At least 40 cases should be included the study especially for complicated cases.
- Method of analysis: Retrospective analysis
- Type of procedure: laparoscopic Cholecystectomy using four port
- The institution were the procedure was practice (preference for those specialist for laparoscopic surgery)
- Laparoscopic Cholecystectomy practice: In all studies laparoscopy Cholecystectomy was performed with a standard technique using four ports.
- Creation of pneumoperitoneum with CO2
- Insertion of port followed by diagnostic laparoscopic
- Holding the funduss by assistant through four ports.

- Dissections of visceral peritoneum
- Dissections of Calot's triangle and homeostasis maintain by using various type of energized instrument
- Clipping and division of cystic duct and artery
- Dissection of GB from liver bed
- Extraction of GB and any spillb stone
- Irrigation of suction of operating field
- Final diagnosis laparoscopy
- Removal of instrument with complete exist of CO2
- Closure of wound

Review of citation

- Carroll BJ: Birth M : Phillips Eh, common bile duct injuries during laparoscopic Cholecystectomoy Surg Endosc 1998 April 12 (4) P 310-3
- Taylor B. Toronto : Ontario CMAJ 1998 Feb. 24 158 (4) P 481-5
- Kwon A.H Uetsujis: Ogura T: Kamiyama Y Intravenous cholangiography for billiary duct animalies Am J Sug 1997 pct 174(4) P 396-401
- Vecchino R; Mac fadgen BV: Latteris: Laparoscopic Cholecystectomoy an analysis on 114.005 cases of united state series. Int Surg 1998 July –sep 83(3) P 215-9
- Lee CM: Stewart L: Waylw: Post Cholecystectomoy abdominal bile collection. Arch surg 2000 may 135(5); P538-42.
- Carroll BJ: Fridman RI: Liberman MA: Phillips Eh: routine cholangiography reduce sequale of CBD injuries Surg Endosc 1996 Dec 10(12) p 1194-7
- Eliana A .Soto. MD Kings county hospital center. Billiary injuring Cholecystectomoy a retrospective study in 124000 cases in 1995.
- Flecher et al in 1999: A routine intraoperative cholangiography –as a protective for complication of Cholecystectomoy: a retrospective study of 19000 cases.
- Derek E. Moore MD: Irane D:wudel MD: A long term of detrimental effect of bilduct injuries. Arch Surg. 2004 Val -139 (476-482).
- Rasool Bakhsh: Zaid MA: Faizalsoud Dar, Zafar Iqbal: Iatrogenic bile duct injury –experience at PIMS – retrospective study of 50 cases of bilduct injury from 1990-2000.
- B-Taylor , Toronto ont, Common bilduct injury during Laparoscopic Cholecystectomoy in Ontario CMAJ 1998 Feb 24: 158(4) 481-485
- Anne Wauge, MD PhD, Magnus Nilsson, MD PhD: A population based of study of 152776 cholecystectomis regarding iatrogenic bile duct injury: Arch Surg 2006: 141: 1207-1213.
- S patel –kenya: Bilduct injuries in laparoscopic Era result of retrospective study with 408 laparoscopic Cholecystectomoy.
- David R. Flum, Md : Thomas Koopsell: MD; Patrich Hoegarty PhD: CBD injuries during laparoscopic Cholecystectomoy and use of intraoperative cholangraphy: Arch surg 2001; 136: 1287-92

- A A Durrani, Nayar Yaqubb, Zubair Hussain, et al: post Cholecystectomy complication and ERCP, a study of 160 patients over a period of 1992 to 2006: Pak Med Sci July-Sep 2007 Vol 23 No 4,614-619.

Discussion

Now day's laparoscopic Cholecystectomy is the gold standard of Gall Stone diseases, though the impact of CBD injuries staggering to both patients and health care system. After reviewing the many articles through internet. I found the so many cases of injuries and there proper management in time can decrease the serious complication and mortality. There are many factors in laparoscopic Cholecystectomy regarding increase risk of CBD injury in compare to Cholecystectomy like:

- Mis interpretation of Anatomy 70%
- Anatomical variation of calot's triangle
- Risk factor
- Technical errors
- Surgeon operates on image rather than reality

Anatomical Variation and Mis Interpretation of Anatomy

GB is the organ having one of the most variable anatomy like:

- Low union with common hepatic duct
- High union with common hepatic duct
- Adherent to common hepatic duct
- Cystic duct absent are very short
- Anterior spiral joining common hepatic duct left side
- Posterior spiral joining common hepatic duct left side
- Intra hepatic GB
- Aberrant cystic duct

Surgeons operate on image rather than reality. Visual psychological studies show that laparoscopic surgeon works on snap interpretation by brain, and success or disasters demand on whether snaps are right or wrong. Snap interpretation will be wrong if there is eye ball degradation. Lack of initial identification and memory of the structure to the points of absolute certainty i.e. relative Anatomy. Though recall the anatomical variation of Calot's triangle but it is more important to remember the relative anatomy to minimize the risk of CBD injury. Though so many articles published regarding per operative cholangiography regarding the CBD injury like: David R Flum , Thomas Koepsell, Patrik Hegarty et al. Arch Surg 2001: 136: 1287-1292 claiming some decrease risk of CBD injury but in my opinion it is not much helpful because surgeon works on relative anatomy rather than absolute anatomy. A little bit advantage of Chalcographic is compensated by the injury to cystic duct during processor and increase operative time of processor and little risk of injury during procedure itself. Though per operative cholangiography is helpful in diagnosis of stones in Biliary duct and to treat them in same time.

Therefore now days it is matter of choice from center to center to do the per cholangiography. In the same way the high resolution ultrasound preoperatively is not much helpful because it is not of much helpful of interpreting the biliary channel it cans only interpretate bil duct dilatation and any stone or debris in spite of cost and specialty involving.

Risk factor

Many study show that the risk factor increases the chance of CBD injury. Many studies like a population base study of 152776 cholestomoty in sweet disk by Anne Waugh MD, PhD, Magnus Nilsson MD PhD, show that old age, male sex, increase the risk of CBD injuries. In the same was injuries three time more, when perform in acute cholecystis compared to elective and even more risk in acute to chronic cholecystitic when GB is in flamed and Fibrosed.

Technical Errors:

All the articles like strasbarg et al in 1995 of more than 124000 Laparoscopic cholecstotmic reported that high rate of biliary injury was due in part of learning curve effect, as surgeon passed through learning curve have reached, steady- state, there has been no significant in the improvement of incident of biliary duct injuries. Major associations have established specific guide lines to avoid this dreaded complication in 1991 Hunter noted that bill duct injury in laparoscopic Cholecystectomy appear to more common in US (.5 to 2.7%) than in Europe .33%. he observed that American teaching stressed cephalic (towards the right shoulder) traction of the infundibulum in GB tenting the CBD in risking its miss identification. European instruction stressed the laterail retraction places the cystic duct at right angle to CBD reducing the likely hood of miss identification.

After studying many articles regarding CBD injury in recommendation of guide line for clinical application in laparoscopy Cholecystectomy by many associations like society of American Gastro Intestinal Indo scopic surgeons, it is found that:

- Try to memories the initial anatomy of calot's triangle surgeon should concern more about relative anatomy than initial anatomy.
- Surgeon must clearly identify the cystic duct at its junction with GB
- A large distended GB should be aspirated and lifted rather than grasped
- The surgeon retract the GB infoundibulum laterally rather than in cephalic direction and avoid force fully pulling up of GB can cause tenting of CBD
- The surgeon should meticulously dissect the cyst duct and cyst artery
- The surgeon should limit the use of all energy sources and prefer pledged dissection near the CBD and recognized that they can cause occult injury
- Use suction and irrigation frequently
- The surgeon should not hesitate to convert to an open operation for technical difficulties, anatomy uncertainties or anatomical anomalies
- The surgeon need to see all structure clearly before dividing any ductal structure
- Per operative cholangiography may be a little helpful to avoid bill duct injury, but it is quite helpful to diagnose bill duct injury at the same time allowing first appropriate treatment at the same time.

- Surgeon should prefer extracharporialnoting as mass legation just below the GB neck in cases of difficult dissection of cyst duct and artery.

Bile Duct

Biliary tree is the whole network of various size ducts branching through liver path is as follows
 Bilicalculi – Canals of hering – interlobular bile duct – intera hepatic bile duct – Rt. And Lt. hepatic bile duct merge to form – common hepatic duct (Exist lever and join) cystic duct form – common bile duct (join pancreatic duct) form ampulla of vater interes deudenum.

The Bismuth classification for bile duct injury is

Type I – CHD stump > 2cm

Type II – CHD stump < 2cm

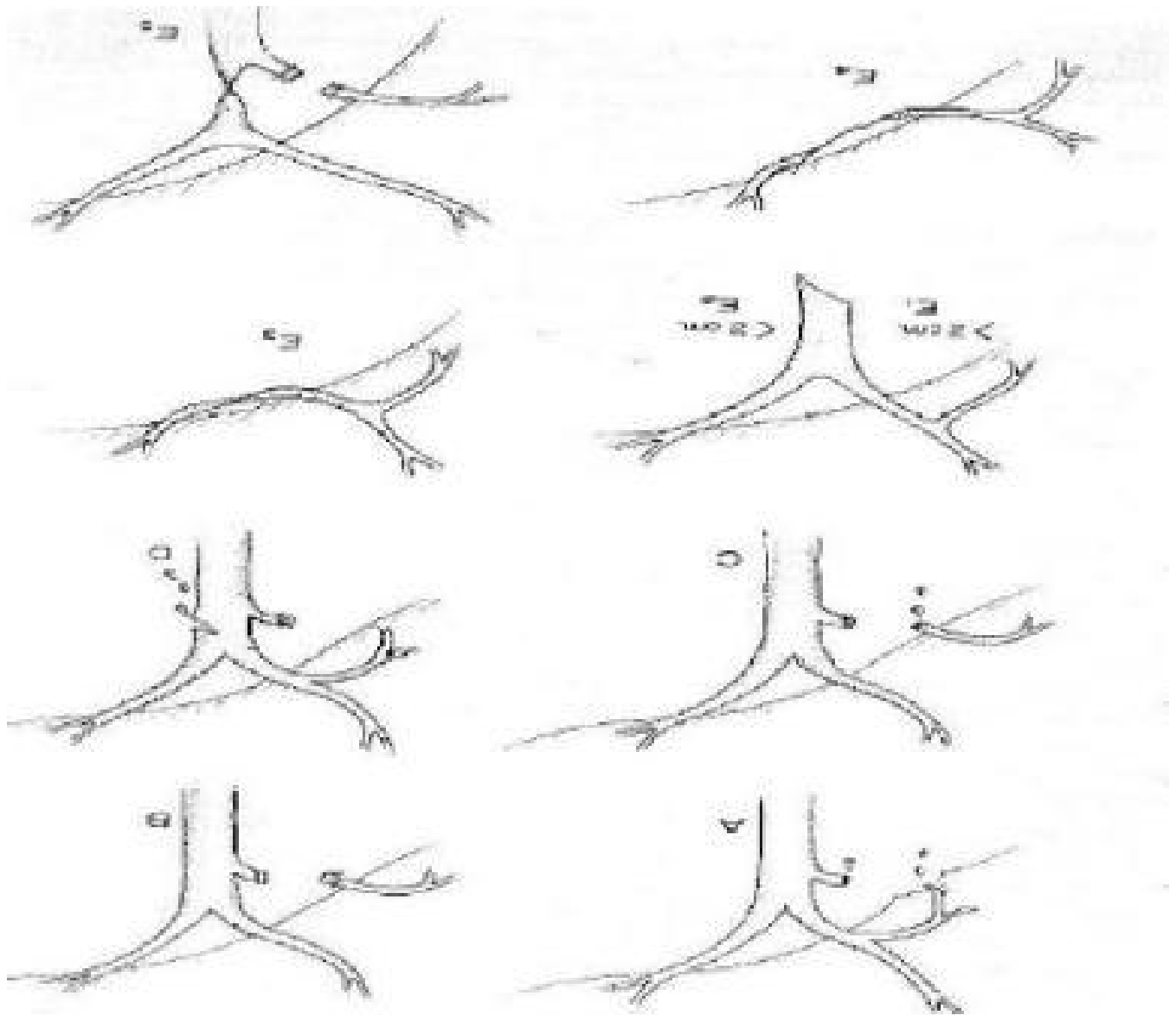
Type III- Hilar Rt. And Lt. duct injury with confluence intact

Type IV- Hilar separation of Rt. And Lt. duct

Type V- Injury to aberrant Rt. Duct ± CBD injury

In 1995 Strasberg and Soper modified the bismuth classification of bile duct injury.

- Type A- bile leak from a minor duct still in continuity with the common bile duct. These leaks occur at the cystic duct or from the liver bed.
- Type B – occlusion of part of the biliary tree. Usually the result of an injury to an aberrant right hepatic duct. In 2% of patients, the cystic duct enters a right hepatic duct rather than the common bile duct-common hepatic duct junction. The aberrant duct may be a segmental duct, a sectoral duct (the right anterior or posterior duct), or even
- Type C – bile leak from duct not in communication with common bile duct. Usually diagnosed in early postoperative period as an intraperitoneal bile collection.
- Type D- lateral injury to extra hepatic bile ducts. May involve the common bile duct, common hepatic duct, or the right or left bile duct.
- Type E – circumferential injury of major bile ducts. This type of injury causes separation of hepatic parenchyma from the lower ducts and duodenum. May be treated by perecutaneous or endoscopic techniques depending on length of stenosis or if.
- Classification of Biliary Duct Injuries:



If complication recognized intraoperatively:

- For high complete transaction roux-en-y hepatojejunostomy
- For lower complete injuries – primary suture repair over T tube
- Long end of T Tube most not be exteriorized from same side
- For partial injuries insertion of T tube and Roux-en-y serosal patch

Strategy to handle complication recognized post operatively

Ultrasound + ERCP + MRCP + PTC

After the detecting the injury or other complication due to bile duct injury, after resuscitation the patient,
with fluid + electrolytes + systemic antibiotic.

Patient should be referred to appropriate center like: secondary or tertiary center for further management accordingly

The principal of treatment is to reestablish a pressure gradient that will favour the flow of bile into the duodenum not outside the leak side like

- Conservative treatment and biliary drainage for 6 week by ERCP stent- insertion

Or PTBD if endoscopic stent application is not possible

- Some time internal stenting with or without sphincterotomy has soon be effective in treatment of small leaks
- A retrospective study by De Palana et al in 2002 showed that sphincterotomy alone was highly effective in producing closure of bile fistulas by reducing endobiliary pressure
- After several weeks, reconstructive surgery like Roux-en-y Cholecystectomy or hepato jejunostomy should be performed if necessary

Conclusion

The principal difference from surgeon's perspective between in laparoscopy and open Cholecystectomy is the lack of three dimensional views of structures to be manipulated. During laparoscopy procedure a surgeon is guided by a two dimensional image seen on a television screen depth perception is affected. That required higher level of coordination and patience.

After diagnosing the CBD injury during operation it should be repaired with appropriate method either open or laparoscopically.

If diagnosed in post operative period then should be always managed in secondary or tertiary center with the operate methods with fully skilled surgeon.

In spite of a little more risk of bile duct injury. Laparoscopic Cholecystectomy is still the gold standard of method for GB stone diseases due to other benefits over open Cholecystectomy.

References

- Prof Dr. R.K.Mishra essentials of laparoscopy New Delhi, M/s all Medical Publisher 2005
- Prof Dr. R. K. Mishra: Textbook of practical laparoscopic surgery New Delhi, Jaypee Brothers Medical Publisher 2008.
- Jordan AB; Hospital charges for laparoscopic and open Cholecystectomy (letter) JAMA 226(24).
- Roslyn JJ, Binns GS, Hughes EF, Sauders-Kirkwood K, Zinner MJ, Cates JA. Open Cholecystectomy: a contemporary analysis of 42,474 patients. Ann Surg. 1993; 218; 129-137
- Strasberg SM, Herti M, Soper NJ, An analysis of the Problem of biliary injury during laparoscopic Cholecystectomy. J Am Coll Surg. 1995;180:101-125
- Windsor JA, Pong J. Laparoscopic biliary injury: more than a learning curve problem. Aust N Z J A Surg. 1998; 68: 186-189

- Adamsen S, Hansen Oh, Funch- Jensen P, Schulze S, stage JG, Ware P. Bile duct injury during laparoscopic Cholecystectomy: a prospective nationwide series. *J Am Coll Surg.* 1997; 184: 571-578.
- Fletcher Dr. Hobbs MS, Tan P, et al. Complication of Cholecystectomy: risks of the laparoscopic approach and protective effects of operative cholangiography: a population- based study. *Am Surg.* 1999;229;449-457
- Archer Sb, Brown DW, Smith CD, Branum GD, Hunter JG. Bile duct injury during laparoscopic Cholecystectomy: results a national survey. *Ann Surg.* 2001;234:549-558
- Wudel LJ Jr, Wright JK, Pinson CW, et al. Bile duct injury following laparoscopic Cholecystectomy: a cause for continued concern. *Am Surg.* 2001;67:557-563
- Richardson MC, Bell G, Fullarton GM, West of Scotland Laparoscopic Cholecystectomy Audit Group. Incidence and nature of bile duct injuries following laparoscopic Cholecystectomy: an audit of 5913 cases. *Br J. Surg.* 1996; 83: 1356-1360
- Calvete J, Sabater L, Camps B, et al. Bile duct injury during laparoscopic Cholecystectomy: myth or reality the learning curve? *Surg Endosc.* 2000;14: 608-611
- Melton Gb, Lilemoe KD, Cameron JL, Saute PA, Coleman J, Sauter PA, Coleman J < Yeo CJ. Major bile duct injuries associated with laparoscopic Cholecystectomy: effect of surgical repair on quality of lie. *Ann Surg.* 2002; 235:888-895.
- Gouma DJ, Go PM Bile duct injury during laparoscopic and congenital Cholecystectomy. *J Am Coll Surg.* 1994; 178: 229-223
- Schol FP, Go PM, Gouma DJ. Outcome of 49 repairs of bile duct injuries after laparoscopic. *World J Surg;* 19: 753-757.
- Woods MS, Traverso WL, Kozarek RA, et al. Characteristics of biliary tract complication during laparoscopic Cholecystectomy: a multi-institutional study. *A, J Surg.* 1994; 167:237-34.
- Caroll BJ, Birth M, Phillips EH. Common bile duct injuries during laparoscopic Cholecystectomy that result in litigation. *Surg Endosc.* 1998;12:310-314
- Chen XR, Lou D, Li Sh, et al. Avoiding serious complication in laparoscopic Cholecystectomy –lessons learned from an experience of 2428 cases. *Ann Acad Med Singapore.* 1996; 25:635-639.
- Sabharwal AJ, Minford EJ, et al. Laparoscopic cholangiography: a prospective study. *Br J Surg.* 1998; 85: 624-626.
- Flowers JL, Zucker KA, Graham SM, et al. Laparoscopic cholangiography: result and indicatina. *Ann Surg.* 1992;215:209-216
- Kullman E, Borch K, Lindstrom E, et al. Value of routine intraoperative cholangiography in detecting aberrant bile ducts and bile duct injuries during laparoscopic Cholecystectomy. *Br J Surg.* 1996; 83:171-175.
- Hunter JG, Avoidance of bile duct injury during laparoscopic Cholecystectomy. *Am J Surg.* 1991;162:71-76
- Lorimer JW, Fairfull-Smith RJ. Intraoperative cholangiography during laparoscopic Cholecystectomy.

- Hawasli A. Does routine cystic duct cholangiogram during laparoscopic Cholecystectomy prevent common bile duct injury? *Surg Laparosc Endosc.* 1993; 3; 290-295.
- Wright KD, Wellwood JM. Bile duct injury during laparoscopic Cholecystectomy without operative cholangiography. *Br J Surg.* 1998; 85:191-194.
- Cox Mr, Wilson TG, Jeans PL, et al. minimizing the risk of bile duct injury at laparoscopic Cholecystectomy. *World J Surg.* 1994; 18: 422-427.
- Perissat J. Laparoscopic Cholecystectomy: the European experience. *Am J Surg.* 1993; 165: 444-449.
- Taylor B. Common bile duct injury during laparoscopic Cholecystectomy in Ontario: does ICD-9 Coding indicate true incidence? *CMAJ* 1998; 158: 481-485.
- Boerma D, Rauws EA, Keulemans YC, et al. impaired quality of life 5 years after bile duct injury during laparoscopic Cholecystectomy: a prospective analysis. *Ann Surg.* 2001; 234: 750-757
- Huang CS, Lein HH, Tai FC, Wu Ch. Long-term results of major bile duct injury associated with laparoscopic Cholecystectomy. *Surg Endosc.* 2003; 17:1362-1367.
- Targarona EM, Marco C, Balague C, et al. How, when, and why bile duct injury occurs: a comparison between open and laparoscopic Cholecystectomy. *Surg Endosc.* 1998; 12:322-326.
- MacFadyen BV Jr. Vecchio R, Ricardo AE, Mathis CR. Bile duct injury after laparoscopic Cholecystectomy: the United States experience. *Surg Endosc.* 1998;12: 315-321.
- Raute M, Podlech P, Jaschke W, et al. Management of bile duct injuries and strictures following Cholecystectomy. *World Surg.* 1993; 17:914-918.
- Trodsen E, Ruud TE, Nilsen BH, et al. Complication during the introduction of laparoscopic Cholecystectomy in Norway: a prospective multicentre study in seven hospitals. *Eur J Surg.* 1994; 160: 145-151.
- Flum DR, Dellinger Ep, Cheadle A, et al. Intraoperative cholangiography and risk of common bile duct injury during Cholecystectomy. *JAMA* 2003; 289: 1639-1644.
- Kullman E, Borch K, Lindstrom E, et al. Value of Routine intraoperative cholangiography in detecting aberrant bile ducts and duct injuries during laparoscopic Cholecystectomy. *Br J Surg.* 1996; 83:171-175.
- Krahenbuhl L, Sclabas G, Wente MN, et al. Incidence, risk factors, and prevention of biliary tract injuries during laparoscopic Cholecystectomy in Switzerland. *World J Surg.* 2001; 25:1325-1330.
- Schol FP, GO PM, Gouma DJ. Risk Factors for bile duct injury in laparoscopic Cholecystectomy: analysis 49 cases. *BR J Surg.* 1994; 81:1786-1788.
- Gronroos JM, Hamalainen MT, Karvonen J, et al. Is male gender a risk factor or bile duct injury during laparoscopic cholecystectomy? *Langenbecks Arch Surg.* 2003; 388:261-264.
- Way LW, Stewart L, Gantert W, et al. Causes and prevention of laparoscopic bile duct injuries: analysis of 252 cases from a human factor and cognitive psychology perspective. *Ann Surg.* 2003; 237:460-469.

For more information please log on to <http://www.laparoscopyhospital.com>

