

# 5

## Abdominal Access Technique

### Section One

Minimal access surgery, a new surgical and interventional approach was called by different name and one of the popular is minimally invasive surgery. However, this terminology is considered inappropriate by Prof. Cuschieri for two reasons. Firstly, it carries connotations of increased safety, which is not the case. Secondly, it is semantically incorrect since to invade is absolute, and indeed such interventions are as invasive as open surgery in terms of reach of the various organs and tissues. The hallmark of the new approaches is the reduction in the trauma of access. Hence, a more appropriate generic term is minimal access therapy.

In minimal access surgery, the technique of first entry inside the human body with telescope and instruments is called access technique. Technique of access is different for different minimal access surgical procedures. Thoracoscopy, retroperitoneoscopy, axilloscopy have different ways of access.

It is important to know that approximately 20 percent of laparoscopic complications are caused at the time of initial access. Developing access skill is one of the important achievements for the surgeon practicing minimal access surgery. First entry or access in laparoscopy is of two types, closed and open access.

### CLOSED ACCESS

In closed access technique, pneumoperitoneum is created by Veress needle. This is a blind technique and most commonly practiced way of access by surgeons and gynecologists worldwide. Closed technique of access merely by Veress needle insertion and creation of pneumoperitoneum is an easy way of access but it is not possible in some of the minimal

access surgical procedures like axilloscopy, retroperitoneoscopy and totally extraperitoneal approach of hernia repair. In general, closed technique by Veress needle is possible only if there is a preformed cavity like abdomen.

### OPEN ACCESS

In this, there is direct entry by open technique, without creating pneumoperitoneum and insufflator is connected once blunt trocar is inside the abdominal cavity under direct vision. There are various ways of open access like Hasson's technique, Scandinavian technique and Fielding technique.

Some surgeons and gynecologists practice blind trocar insertion without pneumoperitoneum. The incidence of injury due to this type of access is much higher. This type of direct trocar entry is practiced by gynecologists for sterilization. Sterilization may be performed because in multipara patients the lower abdominal wall is lax; making the fascia thinner and easy elevation by hand is possible.

Bleeding due to accidental damage to a major vessel during this initial stage is one of the most dangerous complications of laparoscopic surgery.

### Anatomy of Anterior Abdominal Wall

There are three large, flat muscles (External oblique, internal oblique, and transverses abdominis) and one long vertically oriented segmental muscle (rectus abdominis) on each side. Four major arteries on each side are also present which form an anastomotic arcade that supplies the abdominal wall. The superior and inferior epigastric artery and the branches provide the

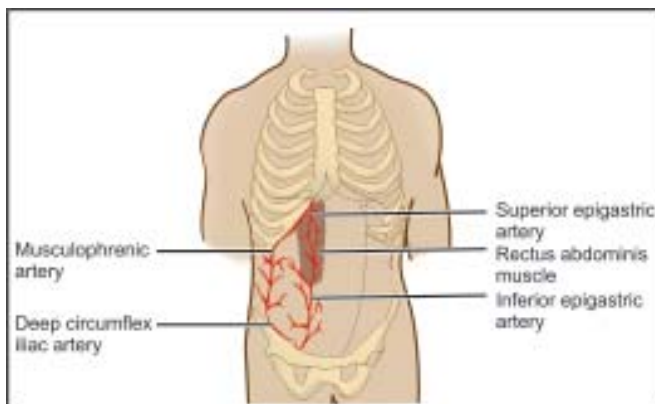
major blood supply to the rectus abdominis muscle and other medial structures (Fig. 5.1).

Among all these arteries, the most important for laparoscopic surgeon is the inferior epigastric artery and vein. The inferior epigastric vessels landmark is less variable compared to superior epigastric. Bleeding from inferior epigastric is a big problem because it is larger in diameter than superior epigastric.

Umbilicus is the site of choice for access. It is the scar remaining after the umbilical cord obliterates. At the level of umbilicus, skin fascia and peritoneum are fused together, with the minimum fat. The midline is free of muscle fibers, nerves and vessels except at its inferior edge where pyramidalis muscle is sometimes found. Trocar site in these locations rarely cause much bleeding. The colon is attached to the lateral abdominal wall along both gutters and puncture laterally should be under video control to avoid visceral injury.

When left subcostal site is chosen for access it should be 2 cm below the costal margin. The costal margin provides good resistance as the needle is introduced. When puncture site lateral to the midline is used, it is prudent to choose location lateral to the linea semilunaris to avoid injury of superior and inferior epigastric vessels. In obese patients, the linea semilunaris may not be visible. In these, location of inferior artery can be localized by careful transillumination.

Access to preperitoneal space is gained by penetrating almost all the layer of abdominal wall except peritoneum. The open technique of access is preferable in this situation. After incising the fascia with the scalpel, fingered dissection is advisable to avoid puncture of peritoneum.



**Fig. 5.1:** Anterior abdominal wall anatomy

## CLOSED ACCESS TECHNIQUE

Creation of pneumoperitoneum is one of the most important steps in laparoscopy. The aim is to build up a good protective cushion to ensure the safe entry of trocar and cannula.

### Veress Needle Insertion

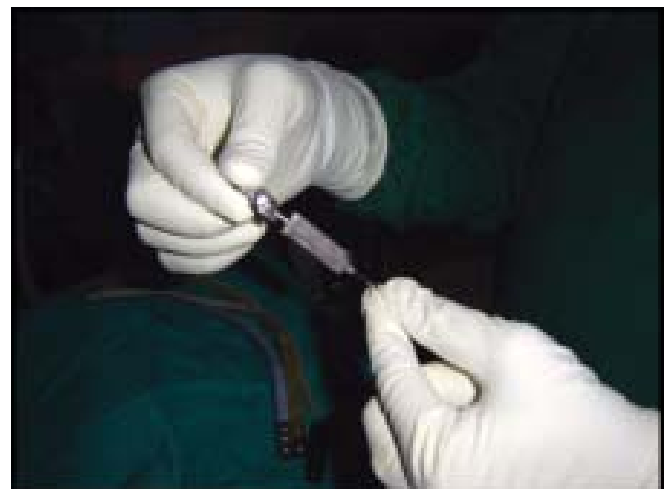The standard method of insufflations of the abdominal cavity is via a Veress needle inserted through a small skin incision in the infraumbilical region. The Veress needle consists of a sharp needle with an internal spring loaded trocar. The trocar is blunt ended with a lumen and side hole. Disposable and non-disposable metal Veress needles are available commercially in different lengths, i.e. long for obese patients, short for thin or pediatric patients.

Before using Veress needle, it should be checked for its patency and spring action (Fig. 5.2). Spring action of Veress needle can be checked by pulling the head out. The disposable Veress needle spring action can be checked by pressing the sharp end against any sterilized draping (Fig. 5.3).

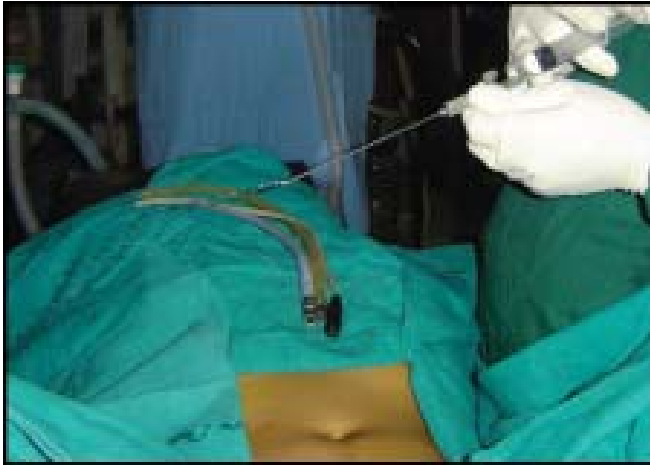Insufflation via the Veress needle creates a cushion of gas over the bowel for insertion of the first trocar. Insufflation then retracts the anterior abdominal wall, exposing the operative field.

### Preparation of Patient

The patient should be nil orally since the morning of surgery. In some of the procedure like LAVH or



**Fig. 5.2:** Spring action of Veress needle should be checked



**Fig. 5.3:** Patency of Veress needle should be checked

colorectal surgery where distended bowel may interfere, it is good to prepare bowel prior to the night of surgery by giving some mild purgative. Bowel preparation can minimize the need of accessory port to retract the bowel.

Before coming to operation theater patient should always void urine. The full urinary bladder may get perforation at the time of insertion of Veress needle or trocar. If the laparoscopic procedure is going to be performed of upper abdomen then Foley's catheterization is not necessary. If gynecological operative surgery or any general surgical lower abdominal procedure has to be performed (like hernia or adhesiolysis) it is wise to insert Foley's catheter.

If surgeon is going to perform any upper abdominal procedure like cholecystectomy, fundoplication, Duodenal perforation, hiatus hernia, etc it is good practice to have nasogastric tube in place. A distended stomach will not allow proper visualization of Calot's triangle and then surgeon has to apply more traction over fundus or Hartman pouch and this may cause tenting of CBD followed by accidental injury. In gynecological or lower abdominal laparoscopic procedure, it is not necessary to put nasogastric tube.

In minimal access surgery, shaving of skin is not must and if necessary it should be done on operation table itself by surgeon.

### Operating Room Set-up

An organized well equipped operation theater is essential for successful laparoscopy. The entire surgical

team should be familiar with the instruments and their function. Each instrument should be inspected periodically for loose or broken tips even if the same instrument was used during a previous procedure. It is necessary to confirm proper sterilization of instruments because the surgeon ultimately is responsible for the proper functioning of all instrument and equipment.

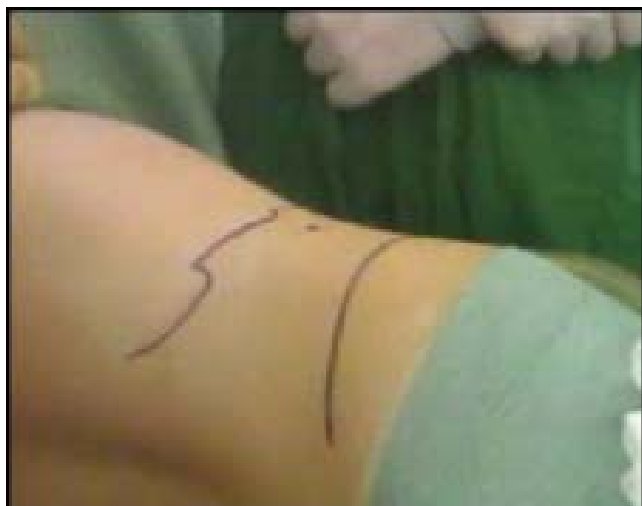The entire instrument should be placed according to wish of the surgeon so that it should be ergonomically perfect for that surgery. The co-axial alignment should be maintained. Co-axial alignment means the eye of the surgeon, target of dissection and monitor should be placed in same axis.

### Patient Position

Initially at the time of pneumoperitoneum by Veress needle, patient should be placed supine with 10-20 degrees head-down. The benefit of this steep Trendelenburg's position is that bowel will be pulled up and there will be more room in pelvic cavity for safe entry of veress needle. It is important to remember that, patient should be placed in head down position only if surgeon is planning to insert veress needle pointing towards pelvis cavity. If surgeon is planning to insert Veress needle perpendicular to abdominal wall as in case of very obese patient or diagnostic laparoscopy in local anesthesia, the patient should be placed in supine position otherwise all the bowel will come just below the umbilicus and there is increased risk of bowel injury.

In gynecological laparoscopic procedures or if laparoscopy is planned to be performed together with hysteroscopy, patient should be positioned in lithotomy position and one assistant should be positioned between the leg of patient. Patient's leg should be comfortably supported by padded obstetric leg holders or Allen stirrups which minimizes the risk of venous thrombosis. In these procedure, surgeon need to use uterine manipulator for proper visualization of female reproductive organs. The assistant seating between the legs of patient will keep on watching the hand movement of surgeon on monitor and he should give traction with the handle of uterine monitor in appropriate direction.

If thoracoscopy or retroperitoneoscopy is planned then patient is placed in lateral position (Fig. 5.4).



**Fig. 5.4:** Patient position in retroperitoneoscopy

### Position of Surgical Team

The laparoscopic surgeon is very much dependent and helpless with eye fixed on monitor. At the time of laparoscopic surgery, surgeon is largely depending on the skill of his assistant. If the surgery is of upper abdomen, French surgeons like to stand between the legs of patient, popularly known as “French position” (Fig. 5.5).

The American surgeons like to operate from left in cases of upper abdominal surgery like fundoplication and hiatus hernia called as “American position”.

It is not wise to remain standing in any one position and surgeon can walk to the other side of operation table to achieve proper ergonomics. In most of the cases at the time of access, surgeon should stand on left side of the patient. If surgeon is left handed, he should stand right to the patient at the time of access. This helps in

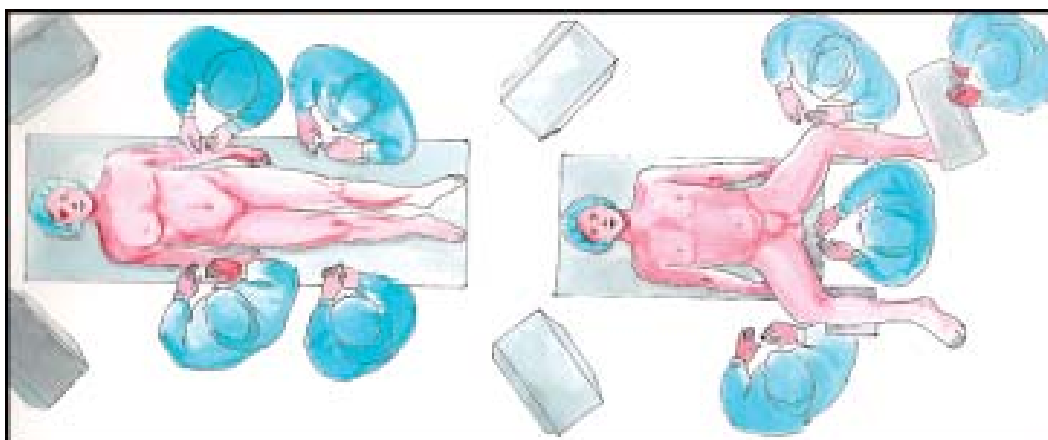
inserting Veress needle and trocar towards pelvis by dominant hand. Once all the ports are in position, the surgeon should come opposite to the side of pathology to start surgery. In cholecystectomy, appendectomy, right sided hernia or right ovarian cyst, surgeon should stand left to the patient. In left sided pathology like left ovarian cyst and left sided hernia it is ergonomically better for surgeon to stand right to the patient (Fig. 5.6).

In most of the upper abdominal surgery, camera assistant should stand left to the surgeon and in lower abdominal surgery he or she should stand right to the surgeon. Camera assistant while holding telescope can pass his or her hand between body and arm of surgeon so that some time surgeon can help him to focus his camera correctly. Camera assistant can be placed opposite to the surgeon to stand but in this case it is better to have two monitor on both the side of patient, one for surgeon and one for camera stand and other members of surgical team.

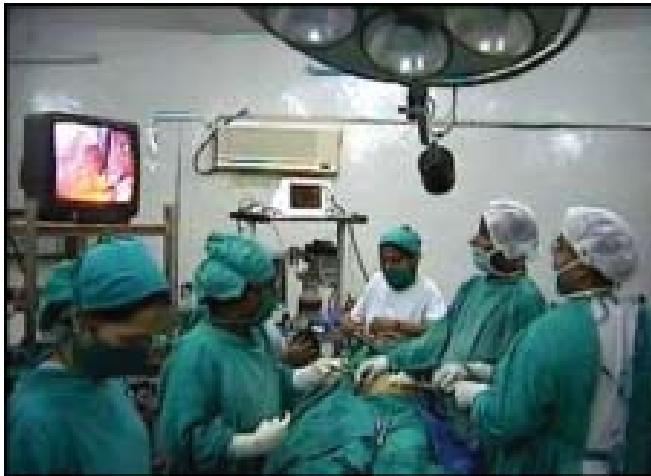The surgeon should work in the most comfortable and less tiring position possible with shoulder relaxed, arms alongside of the body, elbows at 90° angle and forearm horizontal.

### Preparation for Access

Before starting access, abdomen should be examined for any palpable lump. It is wise to tell the patient to void urine before coming to operating room but if the bladder is found full at the time of palpation. Foley’s should be applied. Remember that full bladder may be injured very easily by veress needle or trocar (Figs 5.7A to D).



**Fig. 5.5:** American versus French position

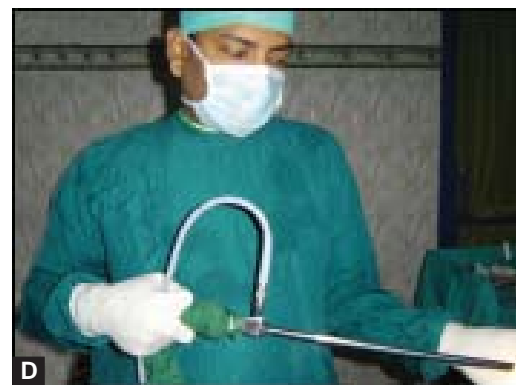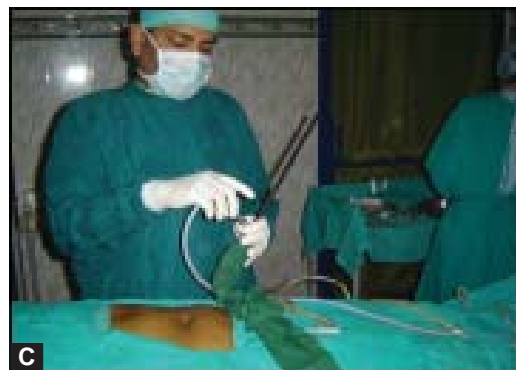

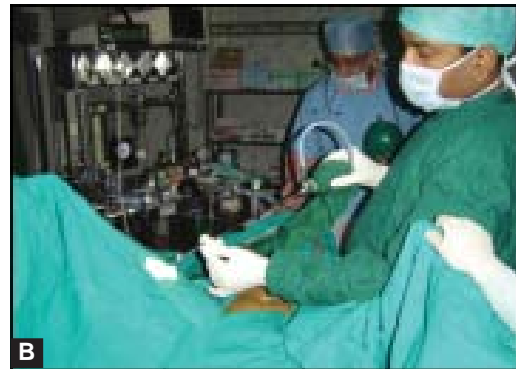
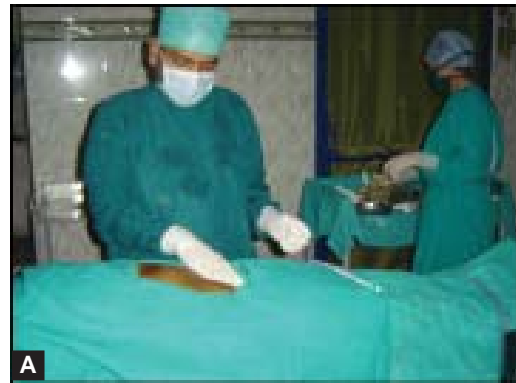**Fig. 5.6:** Surgeons stand left to the patient in most of the right-sided pathology

Once the patient is cleaned, painted, and draped, all the connections should be attached, followed by focusing and white balancing of the camera. At the time of focusing, the distance between the gauge piece and the tip of the telescope should be 6 to 8 cm.

#### Choice of Gas for Pneumoperitoneum

At first, pneumoperitoneum was created by filtered room air. Carbon dioxide and nitrous oxide are now preferred gases because of the increased risk of air embolism with room air.  $\text{CO}_2$  is used for insufflation as it is 200 times more diffusible than oxygen. It is rapidly cleared from the body by the lungs and will not support combustion.  $\text{N}_2\text{O}$  is only 68 percent as rapidly absorbed in blood as  $\text{CO}_2$ .  $\text{N}_2\text{O}$  has one advantage over  $\text{CO}_2$  that it has a mild analgesic effect, and hence no pain if diagnostic laparoscopy is performed under local anesthesia.  $\text{CO}_2$  has the advantage of being non-combustible and allows the concomitant use of electrocoagulation and laser irradiation. For short operative procedures like sterilization or drilling, under local anesthetic  $\text{N}_2\text{O}$  may also be used. During prolonged laparoscopic procedures,  $\text{N}_2\text{O}$  should not be a preferred gas for pneumoperitoneum because it supports combustion better than air.  $\text{CO}_2$  when in contact with peritoneal fluid converts into carbonic acid. Carbonic acid irritates the diaphragm, causing shoulder tip pain and discomfort in the abdomen. Carbonic acid has one advantage also that it alters the pH of peritoneal fluid (acidotic changes) and it is a mild antiseptic, so the chances of infection may be slightly less compared to



**Figs 5.7A to D:** Preparation before access; palpation of abdomen, attachment of cables, focusing and white balancing

any other gas. Helium gas being inert in nature is also tried in many centers but it does not have any added benefit over CO<sub>2</sub>.

### Site of Veress Needle Entry

There are many sites of Veress needle entry tried for Veress needle insertion but central location of umbilicus and ability of umbilicus to hide scar makes it most attractive site for primary port.

Umbilical is good site for access because it is:

- Thinnest abdominal wall (easy access)
- Cosmetically better
- No significant blood vessels
- Ergonomically better (center point of abdomen).

Initially there was controversy regarding use of umbilicus for first port access. First concern was regarding infection. Umbilicus is a naturally dirty area and many surgeons were having this impression that it may cause infection of port site. The umbilical skin cannot be cleaned of all bacteria even with modern iodophor solution. Carson and associates (1997) demonstrated that the bacteria introduced inside the abdominal cavity through this dirty skin but these bacteria do not have many dead cells to act as culture medium to grow and the normal defense mechanism of body destroys these bacteria rapidly. Second fear of using umbilicus was ventral hernia. Umbilicus is the weakest abdominal wall so the chances are more that ventral hernia may develop if umbilicus is used for access. A survey of American Association of Gynecological Laparoscopists members reported in 1994 a study of 3127 surgeons and there were 840

hernia reported. 86 percent of cases of incisional hernia after laparoscopy were due to unrepaired 10 mm or larger port wound.

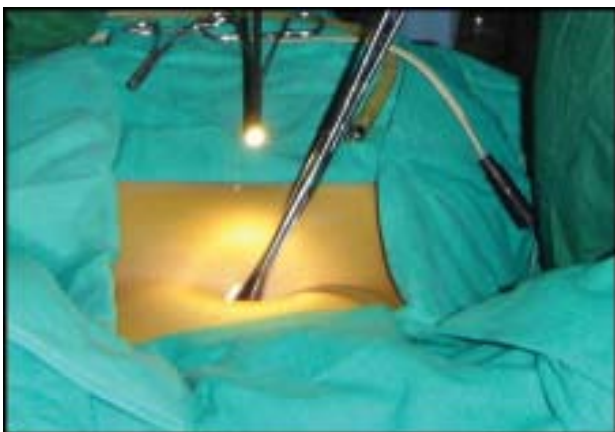
Due to these two possible complications of using umbilicus for access, many surgeons started using supraumbilical or infraumbilical region of abdominal wall for access. Even the port wound of 10 mm away from the umbilical site has reported higher incidence of incisional hernia. Recent study has proved that umbilicus does not have increased incidence of infection or ventral hernia compared to other site if few precautions are taken.

1. Umbilicus should be cleaned meticulously before incision (Fig. 5.8).
2. Rectus sheath of all the 10 mm port should be repaired.
3. If umbilical route is used for tissue retrieval, infected tissue should be removed after putting in endobag. It should not contaminate the port wound.
4. Any hematoma formation at the port wound site should be discouraged by maintaining proper hemostasis.

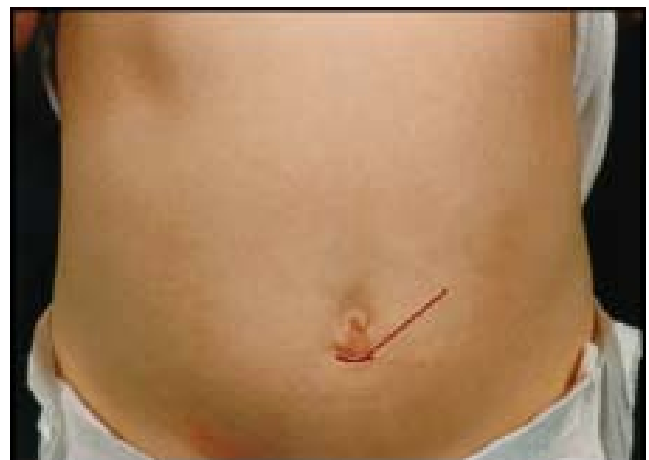### Where in Umbilicus?

- Superior or inferior crease of umbilicus, in non-obese patients (for abdominal procedure).
- Transumbilical in obese patients or if diagnostic laparoscopy is going to be performed under local anesthesia.

In most of the patients, inferior crease of umbilicus is best site of incision. This is called as smiling incision (Fig. 5.9). In obese patient, transumbilical incision is



**Fig. 5.8:** Proper cleaning of umbilicus is necessary before inserting port



**Fig. 5.9:** Smiling incision

preferred because this area has minimum thickness of fat. In obese patient veress needle should be inserted perpendicular to the abdominal wall because if oblique entry is tried, the full length of Veress needle will be some where within the fat pad and there is chance of creation of pre-peritoneal space.

### Stabilization of Umbilicus and Incision

Before incision along the inferior crease of umbilicus it should be stabilized with the help of two Ellis forceps. Once Ellis forceps will hold the umbilicus, the crease of umbilicus will be everted and it is easy to give smiling incision. Initial 1 mm incision with blade no.11 should be given (Figs 5.10A and B).

Some surgeon give 11 mm incision in beginning itself, but this is not good because gas may leak from the side of puncture of veress needle due to tear in rectus and this will interfere with the quadro-manometric indicator of insufflator.

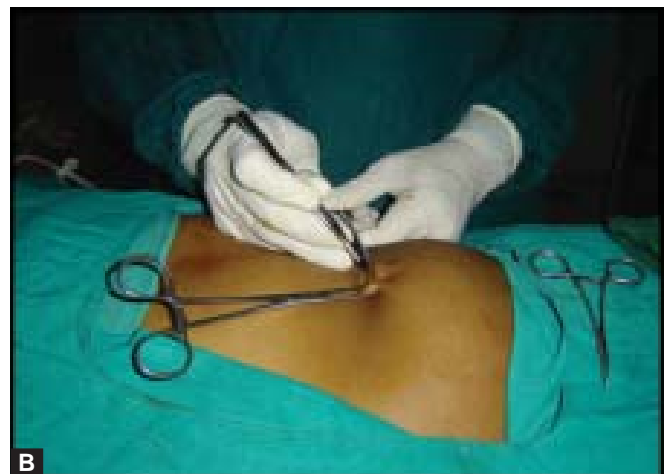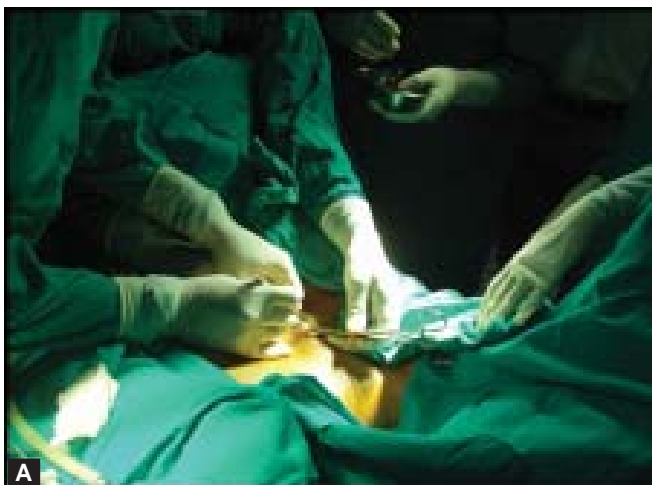Stab wound should be given just skin deep and any puncture of rectus or peritoneum should be avoided. After this initial incision tip, mosquito forceps is introduced to clear the subcutaneous fat and any remaining septa of skin (Fig. 5.11).

### INTRODUCTION OF VERESS NEEDLE

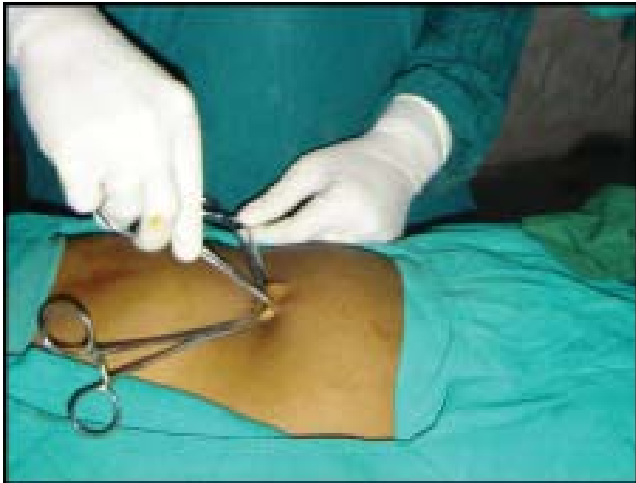Veress needle should be held like a dart (Fig. 5.12). At the time of insertion there should be 45° of elevation angle. Elevation angle is angle between instrument and body of patient. To get an elevation angle of 45° the distal end of the Veress needle should be pointed toward anus.

To prevent creation of pre-peritoneal slip of tip of Veress needle, it is necessary that Veress needle should be perpendicular to the abdominal wall. However, there is a fear of injury of great Vessels or bowel if Veress needle is inserted perpendicular to the abdominal wall. To avoid both the difficulty (creation of pre-peritoneal space and injury to bowel or great vessels), the lower abdominal wall should be lifted in such a way that it should lie at 90° angle in relation to the Veress needle but in relation to the body of patient Veress needle will be at an angle of 45° pointed towards anus. Lifting of abdominal wall should be adequate so that the distance of abdominal wall from viscera should increase. If less than required dose of muscle relaxant is given in muscular patient, lifting of abdominal wall may be difficult. In multipara patient, lifting lower abdominal wall is very easy.

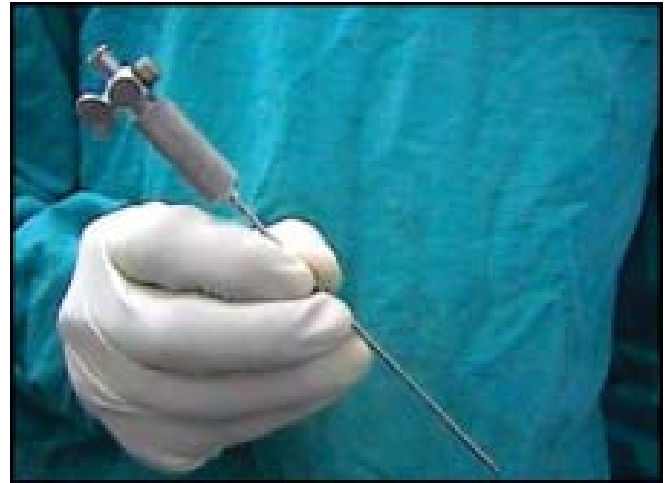
For many years surgeons have been using towel clip to elevate the abdominal wall. This towel clip technique of lifting abdominal was advocated by Johns Hopkins University but after some time it was realized that towel clip technique increases the distance of skin from rest of the abdominal wall more than distance of abdominal wall from viscera. Abdominal wall should be held full thickness with the help of thenar, hypothenar and all the four fingers (Fig. 5.13). It is lifted in such a way that angle between Veress needles to abdominal wall should be 90° and angle between Veress needle and patient should be 45°. At the time of entry of Veress needle surgeon can hear and feel two click sounds. The first click sound is due to rectus sheath and second click sound



**Figs 5.10A and B:** 2mm Stab wound with 11 number of knife



**Fig. 5.11:** Mosquito forceps tip introduced through stab wound



**Fig. 5.12:** Veress needle should be held like a dart

is due to puncture of peritoneum. Anterior and posterior rectus forms one sheath at the level of umbilicus so there will be only one click for rectus.

If any other area of abdominal wall is selected for access surgeon will get three click sounds. Once these two click sound is felt, surgeon should stop pushing Veress needle further inside and he should use various indicators to know how far he has accessed.

### Indicators of Safe Veress Needle Insertion

#### *Needle Movement Test*

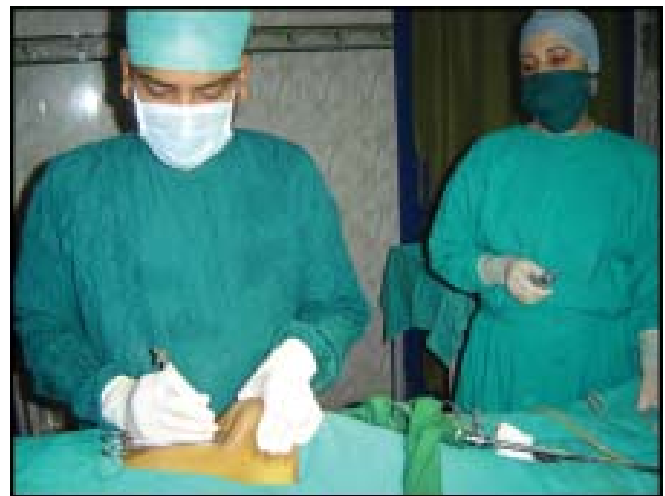Once the Veress needle is inside the abdominal cavity the tip of Veress needle should be free and if surgeon will gently move the tip of needle there should not be feel of any resistance. It is very important to remember that Veress needle should not be moved inside the abdominal cavity much, otherwise there is a risk of laceration of bowel to be punctured (Fig. 5.14).

#### *Irrigation Test*

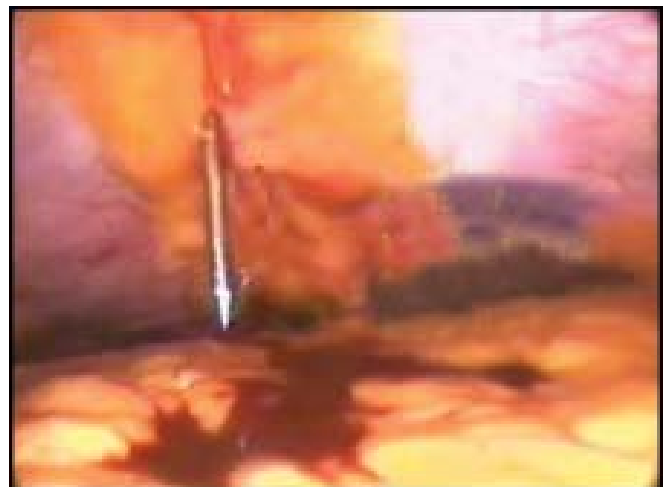A 10 ml syringe should be taken in one hand and surgeon should try to inject at least 5 ml of normal saline through Veress needle. If tip of veress needle is inside the abdominal cavity, there will be free flow of saline otherwise some resistance is felt in injecting saline (Fig. 5.15).

#### *Aspiration Test*

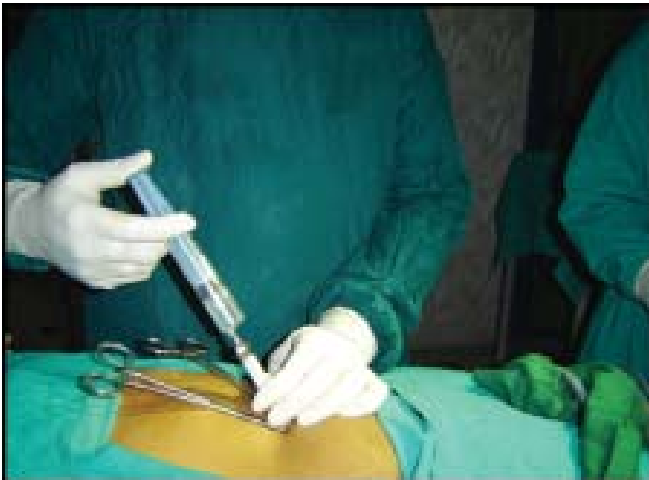After injecting saline, surgeon should try to aspirate that saline back through Veress needle (Fig. 5.16). If the tip of Veress needle is in abdominal cavity, the



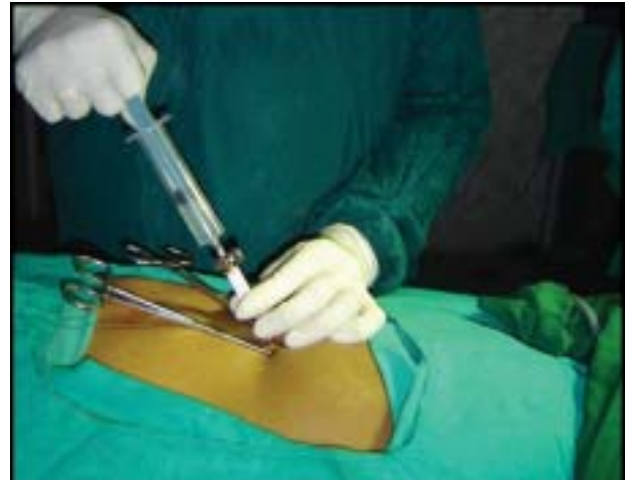**Fig. 5.13:** Lifting lower abdominal wall



**Fig. 5.14:** Bleeding due to injury of omental vessels



**Fig. 5.15:** Irrigation test



**Fig. 5.16:** Aspiration test

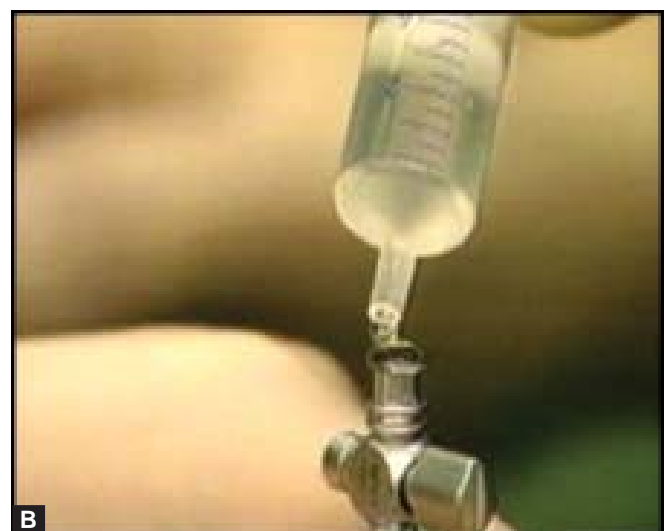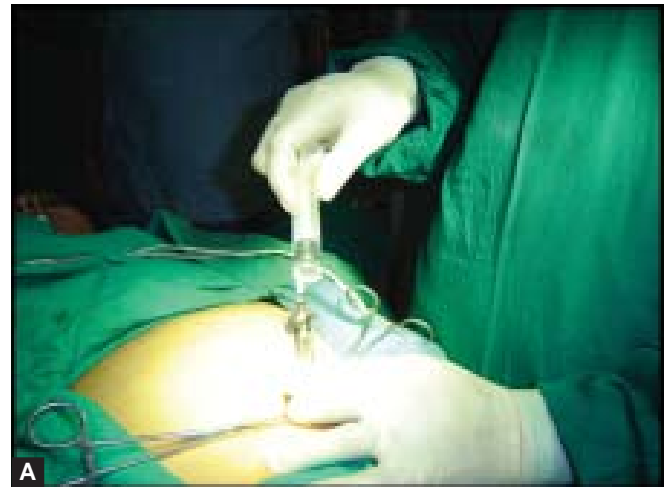irrigated water cannot be sucked. But if it is in preperitoneal space or in muscle fiber of above; the rectus the injected water can be aspirated back. In aspiration test, if more irrigated fluid is coming, then surgeon should suspect ascites, some cyst or perforation of urinary bladder. If fecal matter is seen then perforation of bladder may be the reason and if blood is coming then the Vessel injury is the cause. If any fresh blood or fecal fluid is aspirated in the syringe surgeon should not remove the Veress needle and urgent laparotomy is required. Leaving veress needle in position is helpful in two ways. First it is easy to find the punctured area after laparotomy and secondly the further bleeding will be less.

#### *Hanging Drop Test*

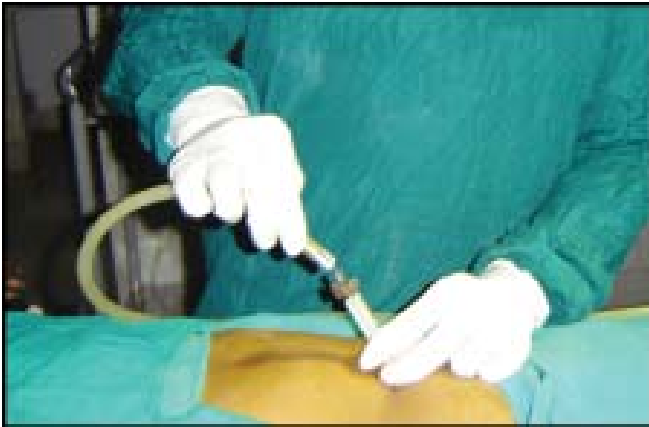Few drops of saline should be poured over the Veress needle and abdominal wall should be lifted slightly, if tip of the Veress needle is inside the abdominal cavity. The hanging drop should be sucked inside because inside the abdomen there is negative pressure. If tip of the Veress needle is anywhere else the hanging drop test will be negative (Figs 5.17A and B).

Once it is confirmed that Veress needle is inside the abdominal cavity the tubing of insufflator is attached and flow is started.

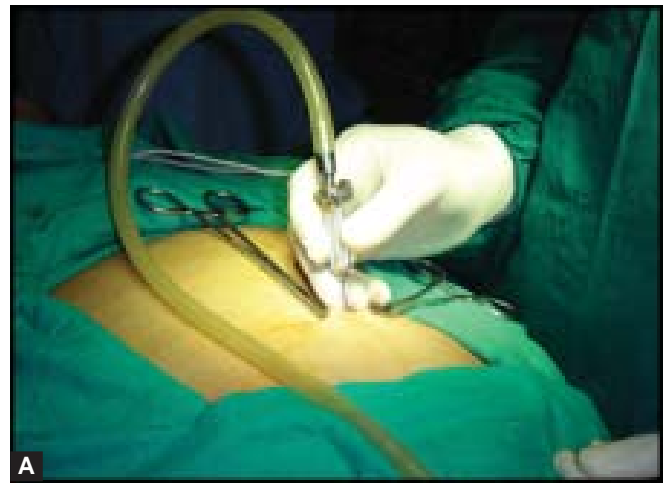
It is important to keep nice hold on Veress needle throughout while gas is flowing; otherwise Veress needle can slip out and may create preperitoneal insufflation (Figs 5.18 and 5.19).



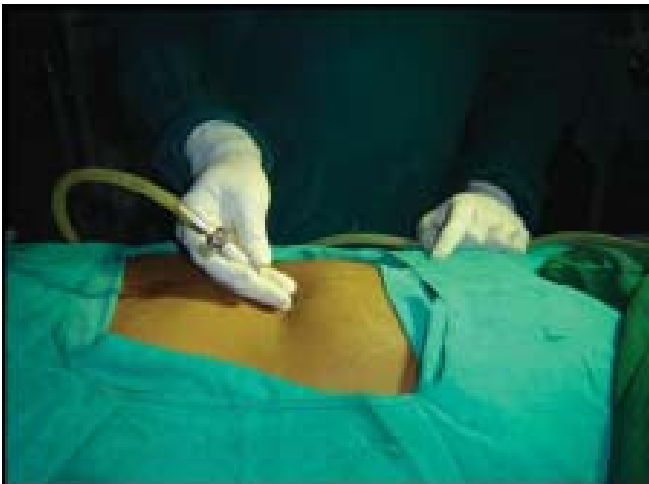**Figs 5.17A and B:** Hanging drop test



**Fig. 5.18:** Attaching gas tubing with careful hold of Veress needle and counter twist over leucostic tube of insufflator tubing



A



**Fig. 5.19:** Beginning of insufflation with careful hold over Veress needle



B

**Figs 5.20A and B:** Quadro-manometric indicators

#### *Insufflation of Gas Test, Quadro-manometric Test*

For safe access, surgeon should always see carefully all the four indicators of insufflator at the time of creation of pneumoperitoneum. If the gas is flowing inside the abdominal cavity there should be proportionate rise in actual pressure with total gas used. Suppose only with the entry of 400 to 500 ml of gas, if actual pressure is equal to preset pressure of 12 mm Hg, that means gas is not going in free abdominal cavity, it may be in pre-peritoneal space or inside omentum or may be in bowel. If gas is flown more than 5 liter without any distension of abdomen that may be due to leakage or gas may be going inside the vessel.

#### *Quadro-manometric indicators of insufflator (Figs 5.20A and B)*

Quadro-manometric indicators are the four important readings of insufflator.

The insufflator is used to monitor:

- Preset insufflation pressure
- Actual pressure
- Gas flow rate
- Volume of gas consumed.

#### **Preset Pressure**

This is the pressure adjusted by surgeon before starting insufflation. This is the command given by surgeon to insufflator to keep intra-abdominal pressure at this level.

The preset pressure ideally should be 12 mm of Hg. In any circumstance, it should not be more than 18 mm of mercury. Good quality insufflator always keeps intraabdominal pressure at preset pressure. Whenever intra abdominal pressure decreases due to leak of gas outside, insufflator eject some gas inside to maintain the pressure, equal to preset pressure. If intra-abdominal pressure increases due to external pressure; insufflator sucks some gas from abdominal cavity, to maintain the pressure to preset pressure.

When surgeon or gynecologist wants to perform diagnostic laparoscopy under local anesthesia, the preset pressure should be set to 8 mm Hg. In some special situation of axilloscopy or arthroscopy, we need to have pressure more than 19 mm Hg.

### Actual Pressure

This is the actual intra-abdominal pressure sensed by insufflator. When veress needle is attached there is some error in actual pressure reading because of resistance of flow of gas through small caliber of Veress needle. Since continuous flow of insufflating gas through Veress needle usually gives extra 4 to 8 mm Hg of measured pressure by insufflator, the true intra-abdominal pressure can actually be determined, by switching the flow from insufflator off for a moment. Many microprocessor controlled good quality insufflator deliver pulsatile flow of gas when Veress needle is connected, in which the low reading of actual pressure measures the true intra-abdominal pressure.

If there is any major gas leak, actual pressure will be less and insufflator will try to maintain the pressure by ejecting gas through its full capacity.

Actual pressures of more than 20 to 25 mm Hg has following disadvantage over hemodynamic status of patient.

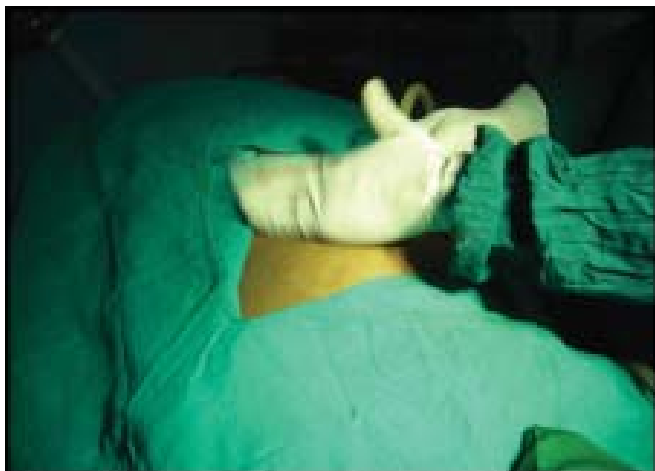
- Decrease venous return due to vena caval compression leading to:
  - a. Increased chance of DVT (Deep vein thrombosis of calf).
  - b. Hidden cardiac ischemia can precipitate due to decrease cardiac output.
- Decrease tidal volume due to diaphragmatic excursion.
- Increase risk of air embolism due to venous intravasation.
- Increased risk of surgical emphysema.

### Flow Rate

This reflects the rate of flow of CO<sub>2</sub> through the tubing of insufflator. When veress needle is attached the flow rate should be adjusted to 1 liter per minute. Studies were performed over animal in which direct IV CO<sub>2</sub> were administered and it was found that risk of air embolism is less if rate is within 1 liter/minute. At the time of access using Veress needle technique sometime Veress needle may inadvertently enter inside a vessel but if the flow rate is 1 liter/minute there is less chance of serious complication. When initial pneumoperitoneum is achieved and cannula is inside abdominal cavity, the insufflators flow rate may be set at maximum, to compensate loss of CO<sub>2</sub> due to use of suction irrigation instrument. This should be remembered that if insufflator is set to its maximum flow rate then also it will allow flow only if the actual pressure is less than preset pressure otherwise it will not pump any gas. Some surgeons keep initial flow rate with veress needle to 1 liter/minute and as soon as they confirm that gas is going satisfactorily inside the abdominal cavity (Percussion examination and seeing obliteration of liver dullness), then they increase flow rate. No matter how much flow rate you set for Veress needle, the eye of normal caliber Veress needle can give away CO<sub>2</sub> flow at maximum 2.5 liter/minute. When the flow of CO<sub>2</sub> is more than 7 liter/minute inside the abdominal cavity through cannula, there is always a risk of hypothermia to patient. To avoid hypothermia in all modern microprocessor controlled laproflattor, there is electronic heating system which maintains the temperature of CO<sub>2</sub>.

### Total Gas Used

As soon as 100 to 200 ml of gas is inside the abdominal cavity surgeon should do percussion of the right hypochondrium and liver dullness should obliterate with tympanic sound (Fig. 5.21). This is the fourth indicator of insufflator. Normal size human abdominal cavity need 1.5 liter CO<sub>2</sub> to achieve intra-abdominal actual pressure of 12 mm Hg. In some big size abdominal cavity and in multipara patients sometime we need 3 liter of CO<sub>2</sub> (rarely 5 to 6 liters) to get desired pressure of 12 mm Hg. Whenever there is less or more amount of gas used to inflate a normal abdominal cavity, surgeon should suspect some error in pneumo-



**Fig. 5.21:** Tapping over right hypochondrium will demonstrate obliteration of liver dullness

peritoneum technique. These errors may be leakage or may be pre-peritoneal space creation or extravasation of gas.

## PRIMARY TROCAR INSERTION

Technical errors in the insertion of trocars after creation of pneumoperitoneum are the most common causes of injury, resulting from inadequate stabilization of the abdominal wall, excessive resistance to trocar insertion, and excessive, misdirected or uncontrolled force applied by the surgeon along the axis of the trocar.

It is important to stabilize the abdominal wall by full insufflation, complete muscle relaxation, to increase the distance between the anterior abdominal wall and the retroperitoneal vessels and the abdominal organs. It is important to ensure that the skin incision is of sufficient length and that the reusable trocar tip is sharp so that no resistance is offered.

Trocar and cannula designs currently available have a number of basic features in common. They come in a variety of sizes and the central trocar may have a pyramidal, conical or rounded tip. They have a valve system and a gas input with a tap (Fig. 5.26).

The disposable cannula has flap valves and care should be taken when passing instruments through the port. Some disposable cannula have a safety system. A cylinder jumps forward after penetration of abdominal wall and forms a shield over the sharp trocar tip. This is not foolproof due to shield lag. In the most recent disposable cannula the trocar itself is spring

loaded. New designs of cannula, some quite minimalist are currently under investigation.

The first trocar and cannula inserted is a 11 mm disposable trocar. This will accommodate a 10 mm telescope and leave sufficient space in the cannula for rapid gas insufflation if required. Following insufflation, the Veress needle is removed and the trocar inserted with care at the same point, using a blind technique.

## Steps of Primary Trocar Insertion

### *Patient Position*

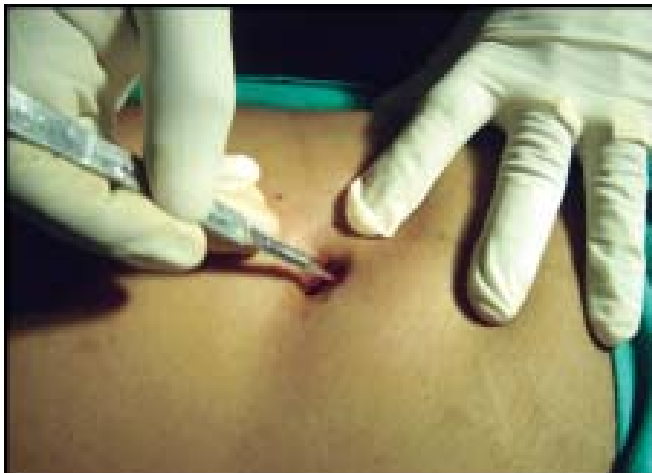As for Veress needle insertion, patient should be placed supine with 10-20 degrees head-down. The cephalocaudal relationship between the aortic bifurcation and the umbilicus has been studied radiologically. The umbilicus is often located directly above or cephalad to the aortic bifurcation, and is consistently located cephalad to where the left common iliac vein crosses the midline. The aortic bifurcation is located more caudal to the umbilicus in the Trendelenburg's position than in the supine position.

### *Site*

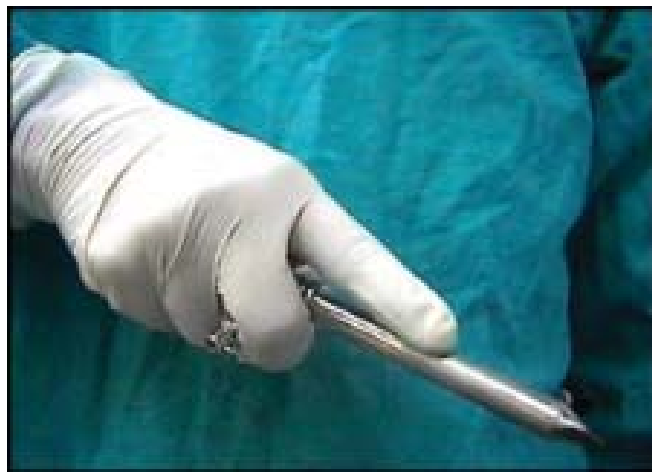The same site of Veress needle entry should be used for primary trocar insertion. Inferior or superior crease of umbilicus can be used in average built patient and transumbilical incision can be used in obese patient. Before introduction of trocar, surgeon should confirm pneumoperitoneum. After adequate distention of abdominal cavity, the actual pressure should be equal to the preset pressure and gas flow should be stopped.

Before introduction of trocar, the initial 1mm stab puncture wound of skin for veress needle should be extended to 11 mm. It should be remembered that most common cause of forceful entry inside the abdominal cavity with primary trocar is small skin incision. To avoid inadvertent injury of bowel due to forceful uncontrolled entry the incision of skin should not be less than 11 mm in size. The skin incision for trocar should be smiling in shape (U shaped) along the crease of umbilicus to get a better cosmetic value (Fig. 5.22).

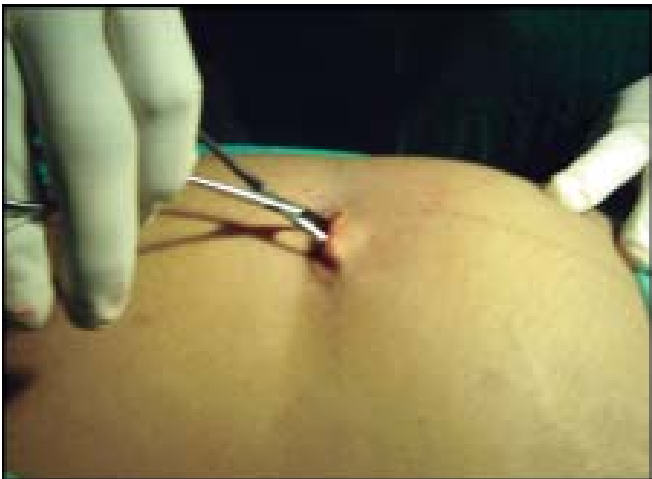After giving 11 mm incision with 11 number blades, surgeon should spread fatty tissues with Kelly clamp (Fig. 5.23).



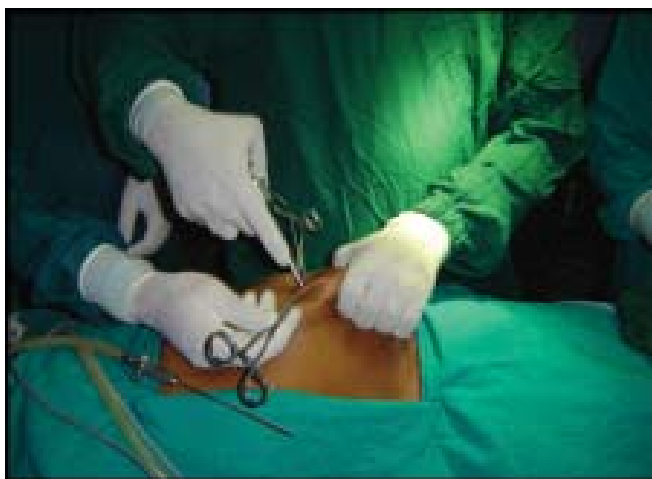**Fig. 5.22:** Smiling incision along inferior crease of umbilicus



**Fig. 5.24:** The trocar and cannula should be held like a pistol



**Fig. 5.23:** Clearing fat and uncut subcutaneous tissue after initial skin incision



**Fig. 5.25:** Direction of trocar insertion

### Introduction of Primary Trocar

Surgeon should hold the trocar in proper way. Head of trocar should rest on thenar eminence, middle finger should encircle air inlet and index finger should point toward sharp end (Fig. 5.24).

After holding the trocar properly in hand, full thickness of abdominal wall should be lifted by fingers thenar and hypothenar muscles. After creation of pneumoperitoneum lifting of abdominal wall is difficult because it slips. To overcome this, it should be grasped to counter the pressure exerted by the tip of trocar.

### Angle of Insertion

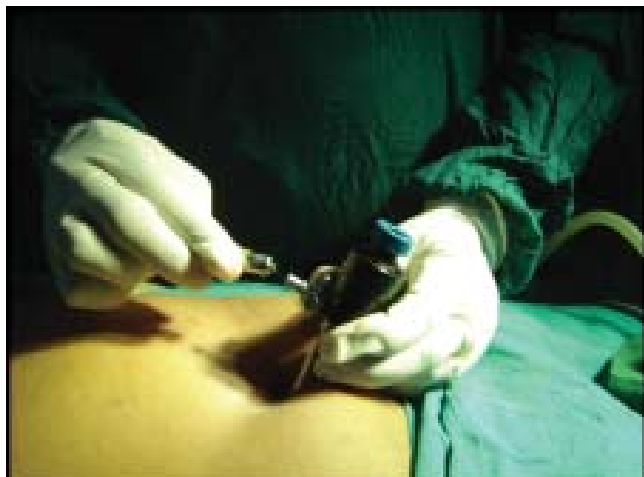Initially angle of insertion for primary trocar should be perpendicular to abdominal wall, but once surgeon

feels giving way sensation, the trocar should be tilted to 60-70° angle.

### Confirmation of Entry of Primary Trocar

- Audible click if disposable trocar or safety trocar is used.
- Whooshing sound if reusable trocar is used (gas passes from the small hole at the tip of pyramidal shaped trocar to the head of trocar).
- Loss of resistance felt both in disposable as well as reusable trocar.

Once the trocar entry in abdominal cavity is conformed, cannula is stabilized with left hand and trocar is removed by right hand. After removing trocar, cannula is pushed slightly further inside the abdominal



**Fig. 5.26:** Attaching leuc lock of insufflator in primary cannula

cavity to prevent coming cannula in pre-peritoneal space with movement of abdominal wall with respiration.

Once cannula is in place tubing of insufflator is attached again and flow is restarted to refill the CO<sub>2</sub> at preset pressure.

Telescope is introduced slowly keeping the oblique cut edge down in case of 30 degree telescope (Fig. 5.27).

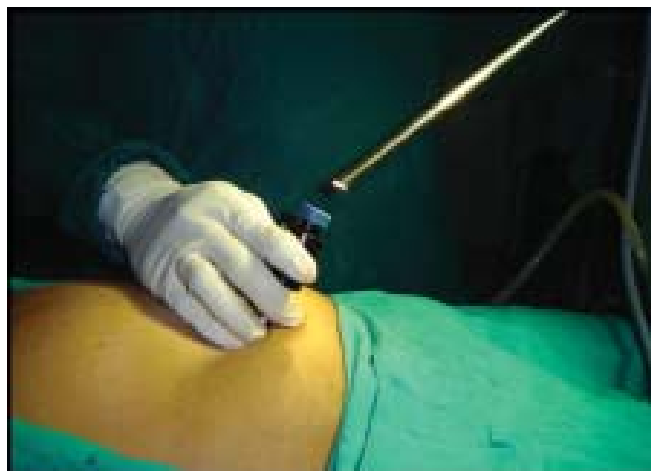Once the telescope is inside, the elevation angle of the telescope should be 90° with panoramic vision. The site just below the entry of primary port is examined for any vessel or bowel injury. Sometime there may be few drop of blood found just below the site of entry but these few drops of blood is trickled blood through umbilical wound. If surgeon has any doubt about perforation of bowel or injury to vessel he should evaluate this area again after putting other ports.

### Working Ports

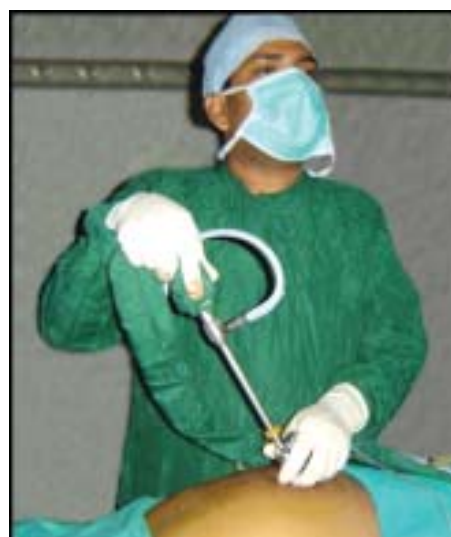To select the site for secondary port, transillumination with illuminated telescope tip should be done first to locate avascular area to avoid injury of subcutaneous vessels.

With the help of mosquito forceps any remaining skin fiber is breached and the subcutaneous fat should be cleared.

Initially the direction of entry of trocar is perpendicular but as soon as the tip of trocar is seen the direction of trocar should be changed towards the anterior abdominal wall to prevent any injury of underlying viscera (Figs 5.25 and 5.30 to 5.32).



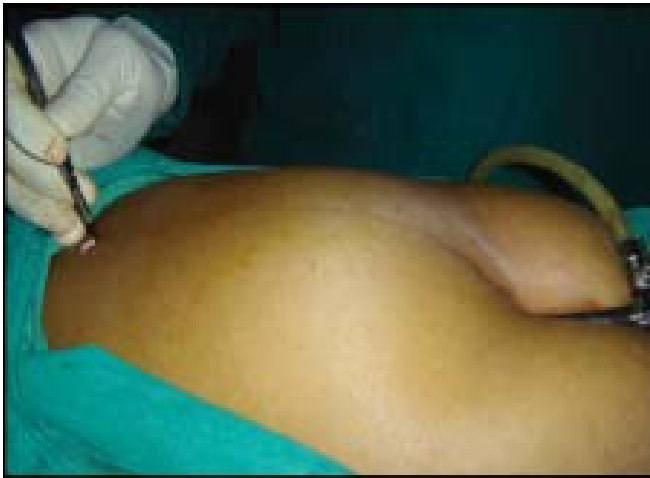**Fig. 5.27:** Introduction of telescope



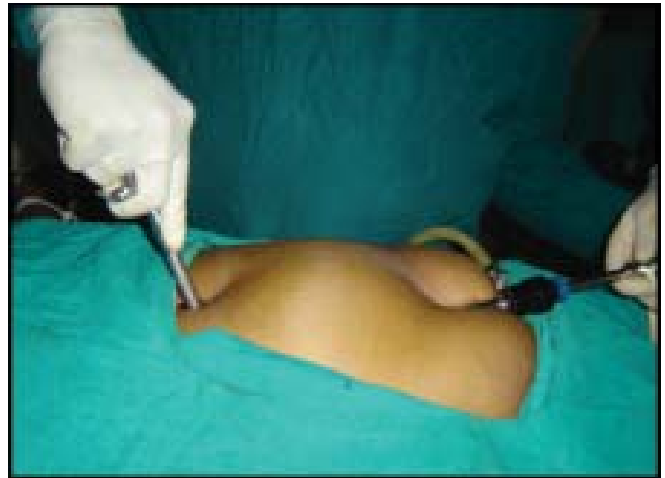**Fig. 5.28:** Inspection just below entry for any possible injury

### Subsequent Ports

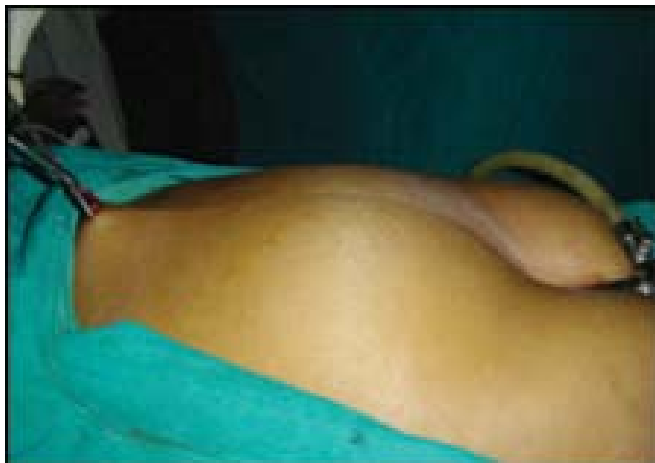Subsequent trocars are inserted under direct vision at locations appropriate for the procedure and to the anatomy of the individual (Fig. 5.29). If the port is on the opposite side of the patient, it can be introduced same way but if surgeon is not able to bend enough to opposite side, his right index finger can be placed over the head of the trocar and left hand should guard the shaft of cannula. With slow rotatory movement of right hand, first the tip of trocar should be perpendicular to the skin but as soon as tip of trocar is seen direction of trocar should changed towards the anterior abdominal wall. Alternatively surgeon can go to another side of the patient and he can introduce the trocar in conventional way (Figs 5.28 and 5.34A and B).



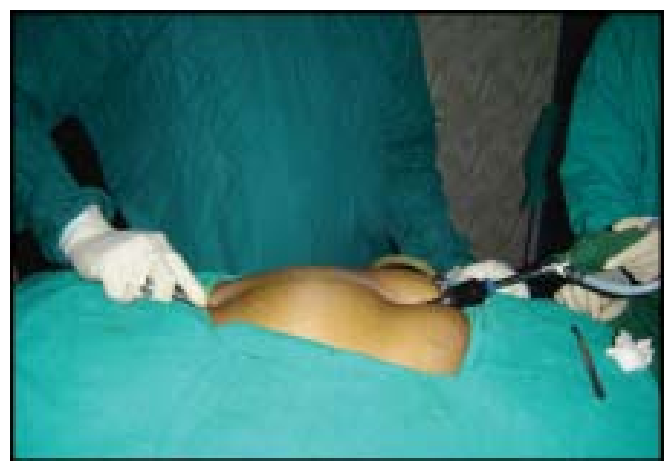**Fig. 5.29:** Incision for secondary ports after transillumination



**Fig. 5.31:** Initially direction of trocar should be perpendicular



**Fig. 5.30:** Clearing subcutaneous tissue under transillumination

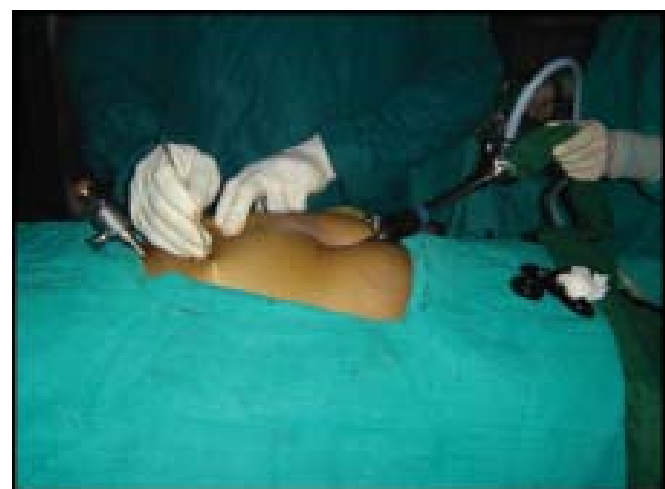

**Fig. 5.32:** As soon as tip of trocar is seen, the direction of trocar should be turned towards the anterior abdominal wall

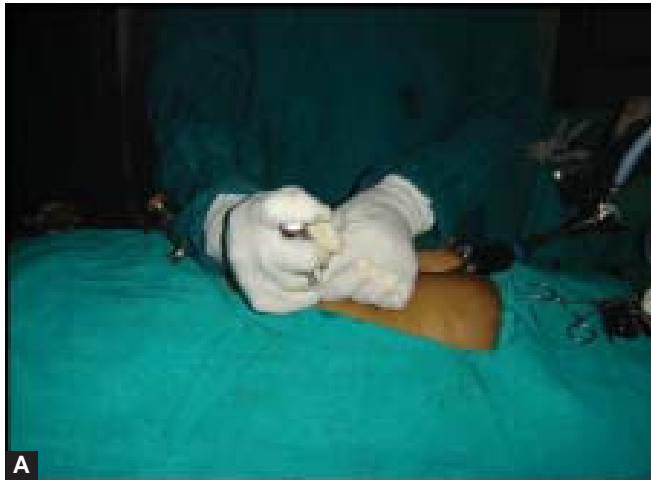In same manner, all the working port should be introduced and instruments are inserted to start the surgery (Fig. 5.35). It should be remembered that distance between two ports should never be less than 5 cm. The “Baseball Diamond Concept” discussed in next chapter is the most appropriate method to decide the site of introduction of working port (Fig. 5.33). The positioning of operative ports is an important factor in determining the ease with which a procedure is carried out. It is a skill which must be learnt.

### Slipping of Port

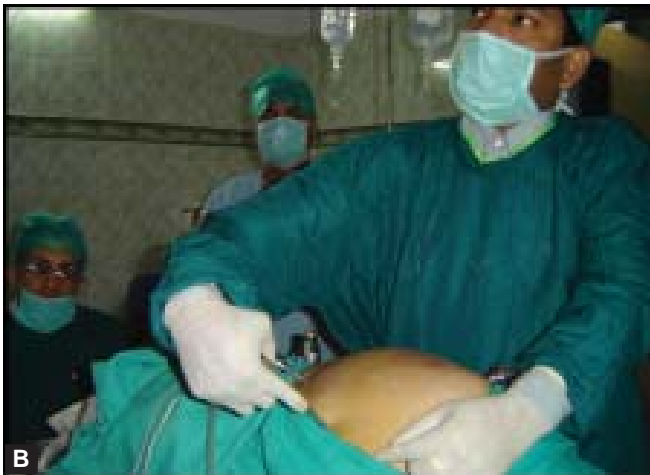Sometimes the port wound becomes bigger than the diameter of cannula and it tends to slip out frequently. In these situation, a simple stitch over skin and fixing of the cannula with the help of sterile adhesive helps



**Fig. 5.33:** Secondary ports should be introduced according to baseball diamond concept

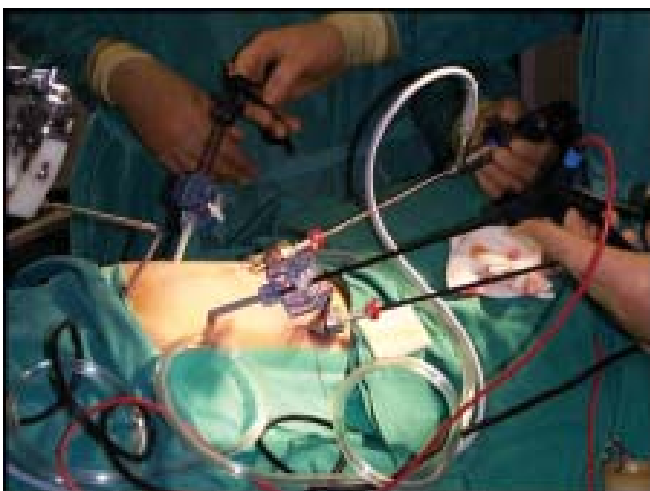

A

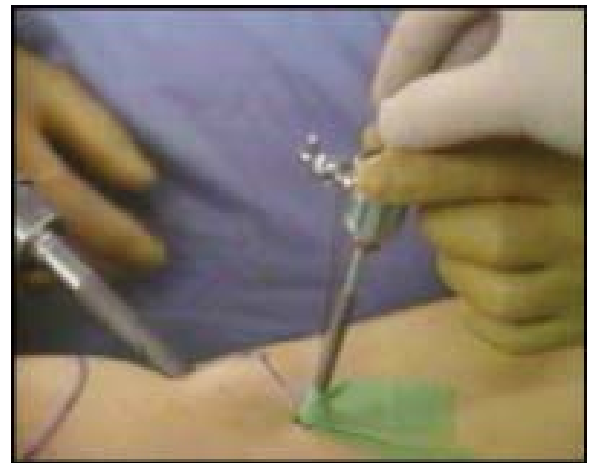

B

**Figs 5.34A and B:** Method of introduction of trocar on opposite side of the patient



**Fig. 5.35:** All the ports and instruments should be positioned properly without entangling each other



**Fig. 5.36:** The port can be stabilized with the help of stay suture and sterile adhesive plaster

(Fig. 5.36). In pediatric laparoscopic surgery, stabilizing the port is necessary.

Non-disposable metal cannula have trumpet or flap valves. The flap valves can be manually opened when introducing or removing an instrument. This avoids damaging delicate instruments like tip of telescope or blunting sharp instruments like aspiration needle and scissors. A reducer tube is used with large cannula to maintain the gas seal and this automatically opens the valve.

A number of cannula modeled on the Hasson cannula is available for use during open laparoscopic procedures. Different sized converters (gaskets) are available for disposable cannula to maintain the gas seal.

Open access technique for primary developed by Hasson in 1974. Open access technique is similar to mini-laparotomy and the cannula is introduced inside.

Hasson's technique involves direct open visualization of the tissues at every layer until the peritoneum is opened, followed by placement of anchoring sutures in the fascia to secure a conical collar (Fig. 5.37). The trocar is then placed through the collar to establish pneumoperitoneum and access. Disadvantages include persistent uncontrolled carbon dioxide leakage in many cases, increased incision size and increased time for placement.

### Advantages of Open Technique

1. Definite, small risk of injury with blind Veress needle technique irrespective of experience.

2. Particularly useful in previous abdominal surgery or underlying adhesions.
3. The incidence of injury to adhesion although not eliminated is significantly reduced by entry into the peritoneal cavity under direct vision.
4. There is a decreased risk of injury to the retroperitoneal vessels. The trocar is blunt and the angle of entry allows the surgeon to maneuver the cannula at an angle, which avoids viscera, while still assuring peritoneal placement.
5. The risk of extraperitoneal insufflation is eliminated. Placement under direct vision ensures that insufflation of gas is actually into the peritoneal cavity.
6. The likelihood of hernia formation is decreased because the fascia is closed as part of the technique.
7. Increasing number of surgeons performing laparoscopy without experience and in these group open technique may be easy.
8. Useful in muscular man and children with strong abdominal wall.
9. Useful for gynecologists or surgeon lacking sufficient upper arm strength to elevate the abdominal wall of patient.

An open technique, which involves creating a mini-laparotomy into which a special cannula is inserted, may be adopted. This procedure has its own complications and requires skilled execution.

The Hasson trocar system was initially developed for laparoscopy in patients who have had a previous laparotomy. After seeing benefit of open access technique, many surgeons started using open access technique routinely in all their patients. An access wound was made using traditional open techniques and the Hasson trocar and cannula was designed to both fix the port and seal this larger wound round the port. It requires the use of sutures to prevent slippage of port. This involved making a small entry wound directly through the scar tissue of the umbilicus and then dilating this up by passage of a blunt, preferable conically tipped trocar and cannula (Fig. 5.41).

### Steps of Open Access Technique

A transverse incision is made in the sub-umbilical region and the upper skin flap is retracted with a 4 inch Allis forceps. The lower flap is retracted using a small right angled retractor. Subcutaneous tissue is dissected till



Fig. 5.37: Hasson's trocar and cannula

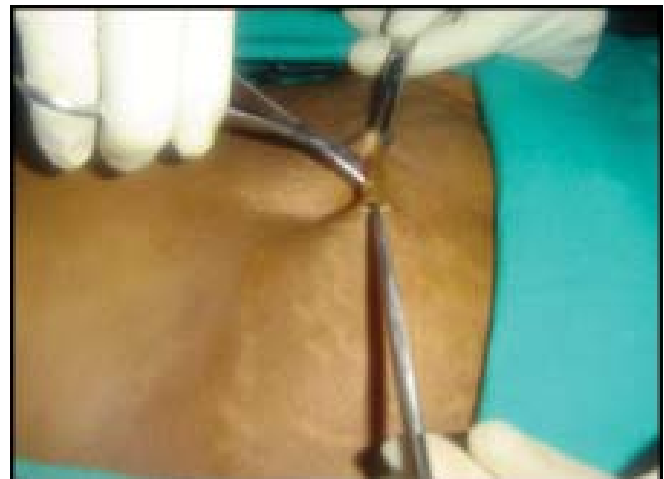
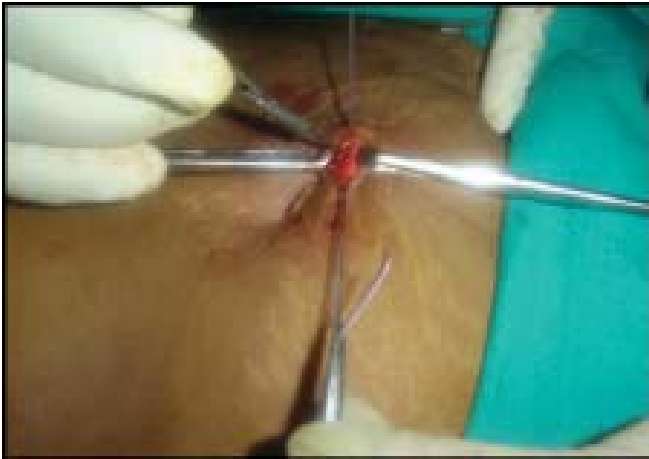
Fig. 5.38: Transverse infraumbilical incision

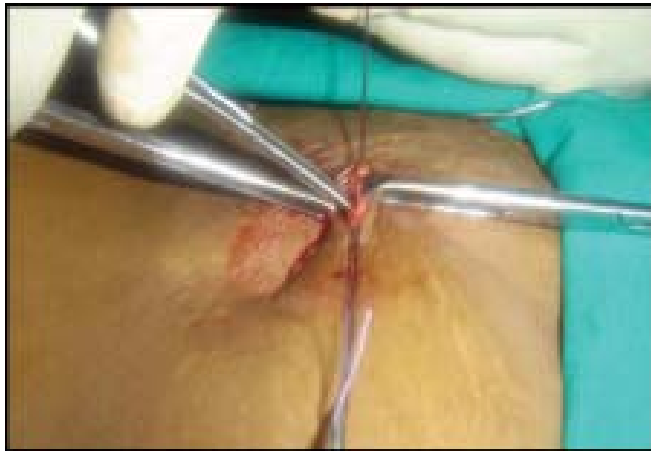the linea alba and the rectus sheath is visualized. Stay sutures are taken on either side of the midline.

### Transverse incision for Open Access

- Stay suture is given both the end of transverse incision (Fig. 5.38).
- Both the stays are pulled up to make a bridge like elevation of rectus.
- Rectus sheath is incised in the midline along the line of linea alba pointing upwards. Incision should not penetrate the peritoneum; otherwise any adhesion with the peritoneum may be punctured (Fig. 5.39).

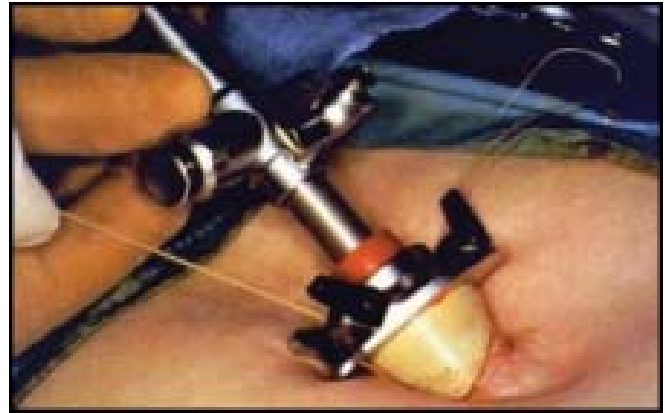

**Fig. 5.39:** Rectus is pulled up by two stay sutures on both the side and rectus is cut in midline longitudinally

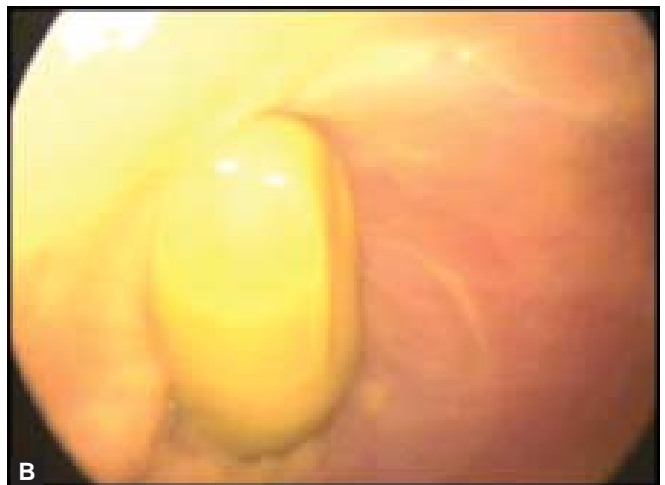
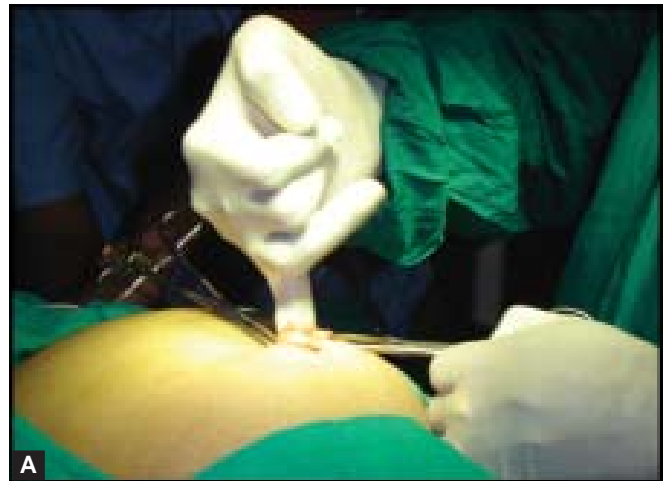
**Fig. 5.40:** Digging of hemostat to puncture peritoneum

- A hemostat is stabbed into the peritoneum, holding the stays up (Fig. 5.40).
- The give-way of the peritoneum can be felt as peritoneum is perforated and then the hemostat is opened to widen the opening.
- Surgeon should insert his finger to feel all around inside the abdominal cavity to feel any possible adhesion (Figs 5.42A and B).
- Small tiny adhesion felt can be broken with gentle sweeping movement of finger. Blunt trocar-cannula should be inserted for the first port after visualizing the intraperitoneal viscera.
- Care is taken not to make a big incision; cannula dilates the smaller incision to give an airtight fit.
- If incision is big, a purse string suture should be applied to hold the port in proper position.



**Fig. 5.41:** Hasson's Cannula in proper position



**Figs 5.42A and B:** Finger insertion after open access will confirm adhesion

#### *Open Fielding Technique*

This technique developed by Fielding in 1992 involves a small incision over the everted umbilicus at a point

where the skin and peritoneum are adjacent. Fielding technique is useful in patients with abdominal incisions from previous surgery provided there is no midline incision, portal hypertension and reanalyzed umbilical vein, and umbilical abnormalities, such as urachal cyst, sinus or umbilical hernia. Thorough skin preparation of the umbilicus is carried out and the everted umbilicus is incised from the apex in a caudal direction. Two small retractors are inserted to expose the cylindrical umbilical tube running from the undersurface of the umbilical skin down to the linea alba. This tube is then cut from its apex downwards towards its junction with the linea alba. Further, blunt dissection through this plane permits direct entry into the peritoneum. Once the peritoneal cavity is breached, the primary port can be inserted directly and insufflation started. A blunt internal trocar facilitates insertion of this port and an external grip that can be attached to the port assist to secure it in position. Suture is usually not required to prevent gas leakage because the umbilicus has been everted so the angle of insertion of the laparoscopic port becomes oblique and the incision required is relatively small. However, one may be needed to stabilize the port.

access was advocated by Palmer in the 1940s because visceral parietal adhesions are rarely encountered in this area (Fig. 5.43).

In addition, some authors feel that because the abdominal wall in the area is supported by the rigid thoracic wall, insertion of the needle is more controlled than in the periumbilical area.

In cases where umbilical entry is contraindicated, it is preferred to use left upper quadrate for entry of Veress needle.

The Veress needle is introduced through left hypochondria, i.e. Palmers point. Special care should be taken that there should not be hepatosplenomegaly (Figs 5.44 and 5.45).

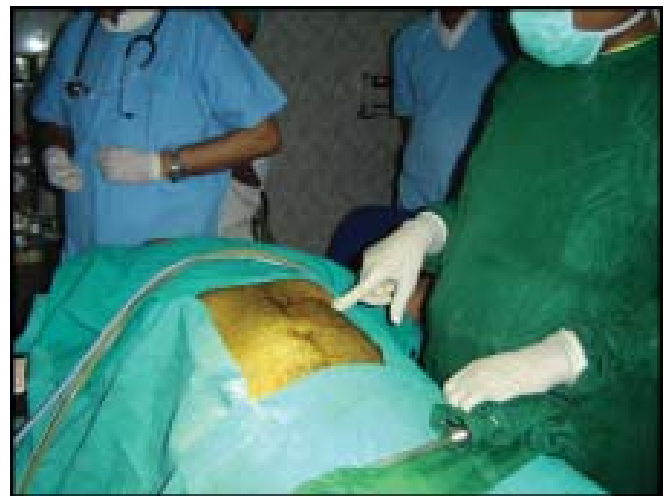

Fig. 5.43: Palmers point of access

### The Scarred Abdomen

Additional precautions are necessary during the access procedure in patients with abdominal scars. It may be inadvisable to insert the Veress needle below the umbilicus in a patient with a scar in this area (or an umbilical hernia). Insufflation through unscarred such as subcostal region, or if this is scarred, the iliac fossae is better. A general guideline is to choose the quadrant of the abdomen opposite to that of the scar.

### Contraindications of Umbilical Entry

- Previous midline incision
- Portal hypertension with reanalyzed umbilical artery with advanced cirrhosis of the liver
- Umbilical abnormalities viz. urachal cyst, sinus, hernia.

## PNEUMOPERITONEUM IN SPECIAL CONDITIONS

### Palmer's Technique

A small incision is made to allow the insertion of the Veress needle through left sub-costal margin. This

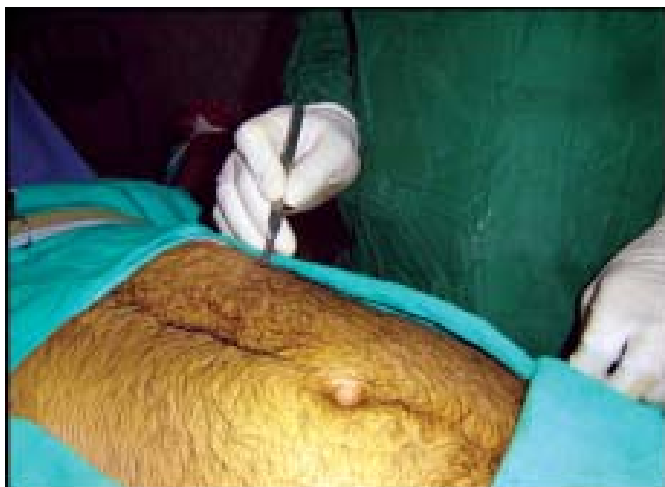
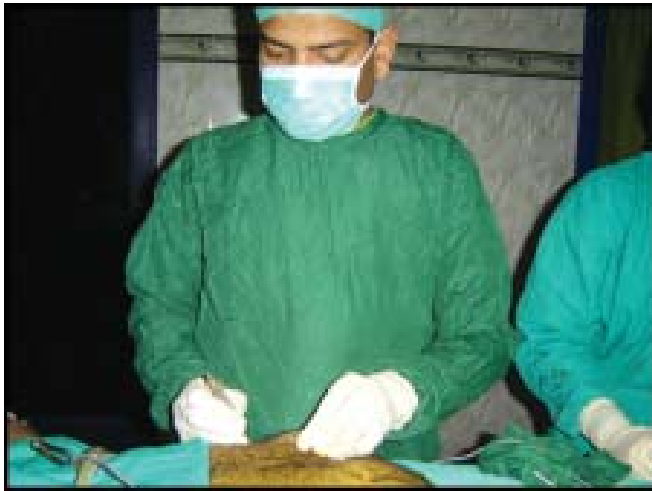
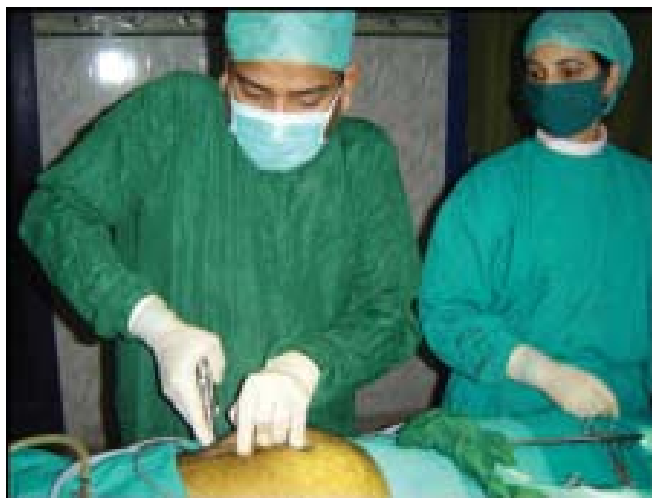Fig. 5.44: A stab wound of 2 mm is given over palmers point



**Fig. 5.45:** Veress needle introduction in right hypochondrium



**Fig. 5.46:** After achieving proper pneumoperitoneum the trocar and cannula is introduced perpendicular to abdominal wall

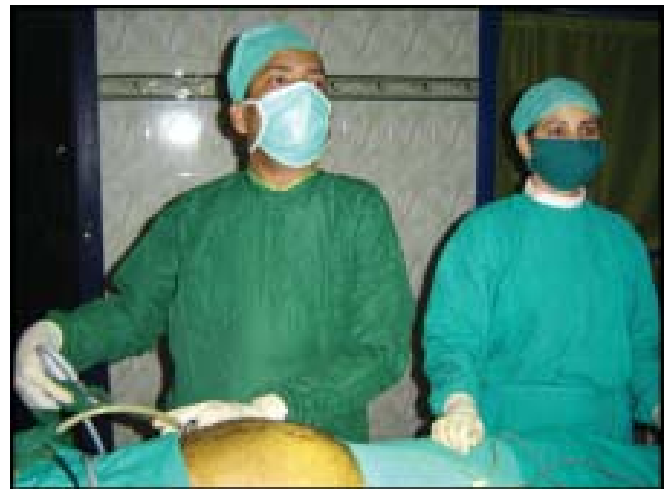After access, umbilicus site is re-checked for any adhesion or other abnormalities. If necessary, umbilicus port may be introduced under vision (Fig. 5.47).

#### *Diagnostic Laparoscopy may be Performed Under Local Anesthesia*

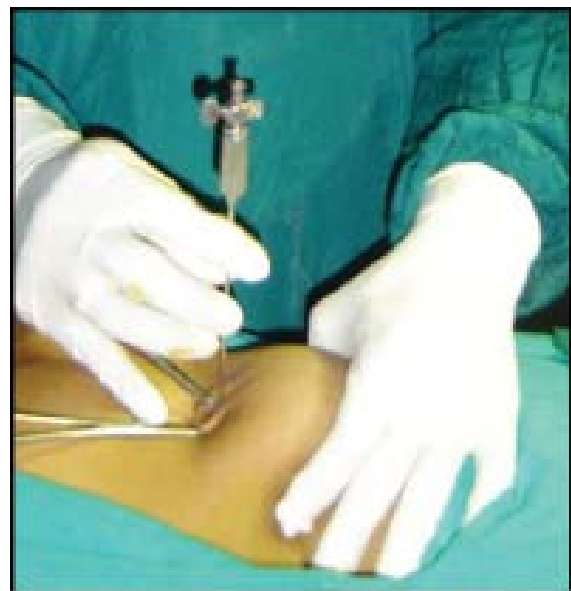Intravenous sedation should be given, Veress needle and trocar should be inserted perpendicular to skin and slow insufflation 0.5 L/minute should be administered to prevent pain (Fig. 5.46). Pressure should not exceed 8 mm Hg otherwise the patient will feel pain. N<sub>2</sub>O can be used if diagnostic laparoscopy is planned under local anesthesia because it has an analgesic effect.

#### *Obese Patients*

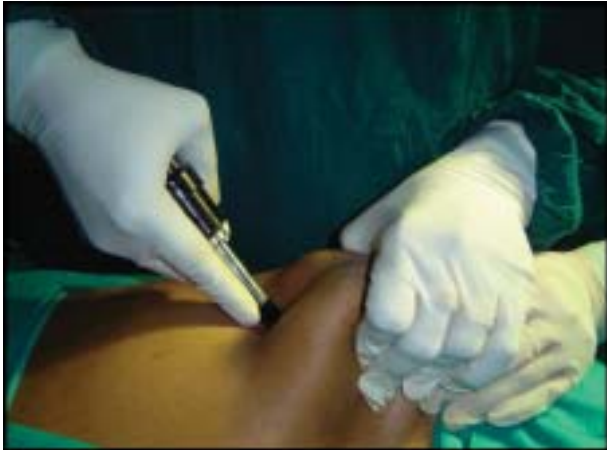In obese patient incision site should be transumbilical (base of umbilicus) for the insertion of Veress needle, because it is the thinnest abdominal wall and even in obese patient, the amount of fat in transumbilical region is less compared to other areas of the abdominal wall. Direction of Veress needle entry in obese patient should be perpendicular to abdominal wall and patient should be in supine position not in Trendelenburg's position (Fig. 5.48). Once the Veress needle is inside pneumoperitoneum should be created up to



**Fig. 5.47:** After access through palmer's point umbilicus should be inspected for any possible adhesion



**Fig. 5.48:** Veress needle should be introduced perpendicular in obese patient



**Fig. 5.49:** Assistant hand should be asked for help, to lift the abdominal wall in obese patients

18 mm Hg. Once the actual pressure is equal to preset pressure and at least 1.5 to 3 liter of gas is introduced, Veress needle is removed. After removing Veress needle the initial incision is enlarged up to 11 mm.

After enlarging the initial incision, fat should be cleared up to anterior rectus sheath with the help of hemostat and little finger.

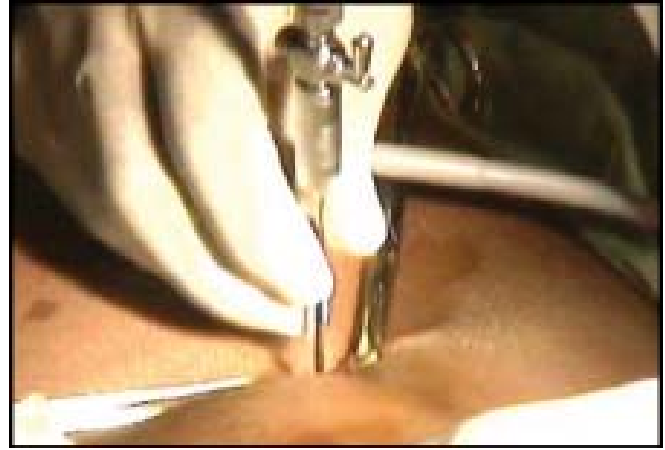In obese patients, it is difficult to lift the abdominal wall alone, assistant's hand should be asked for help to have a better grip (Fig. 5.49).

### ENTRY IN CASES OF MORBID OBESITY

In morbid obese patient, the umbilicus is well below the aortic bifurcation in supine position. Perpendicular entry of Veress needle is necessary. In morbid obese patient, it is virtually impossible to lift the abdominal wall and veress needle need to be introduced perpendicular to the abdominal wall transumbilically without lifting. At least 18 mm Hg pressure is necessary to leave the heavy abdominal wall in case of morbid obese patient (Fig. 5.50).

#### Ultrasound Visceral Slide

There is a simple preoperative test that can help to identify a safe region for Veress needle insertion in the scarred abdomen. The preoperative detection of anterior abdominal wall adhesions by ultrasonic scanning is a simple and reliable technique of ultrasonic detection and mapping of abdominal wall adhesions.



**Fig. 5.50:** In morbid obese perpendicular entry of Veress needle should be without lifting the abdominal wall

Once the Veress needle has been inserted, there should still be concern about the risk of causing damage with the trocar. The following techniques have been described for this situation.

#### Sounding Test

A fine spinal needle, attached to a saline filled syringe, is passed into the inflated abdomen. As the needle is slowly advanced, while aspirating, a stream of bubbles is seen in the saline until the needle tip contacts tissue. The needle is then withdrawn towards the surface and the process repeated several times, in different directions, thereby "mapping" the gas filled cavity and any solid structures.

#### Visually Guided Entry

Optical trocars are used for visual guided entry (Figs 5.51 and 5.52). These permit smaller skin incisions and better visualization of tissues as they are penetrated, and have been shown in large series to be safe and fast way to access the peritoneal space. Injuries can be recognized immediately, thereby reducing their potential morbidity. Disadvantages include the inability to remove the trocar during its initial advancement, which may change the original tract and confuse orientation, in addition to making it difficult to recognize the peritoneal layer. FDA reports also confirm deaths from major vascular injuries associated with the use of optical trocars.

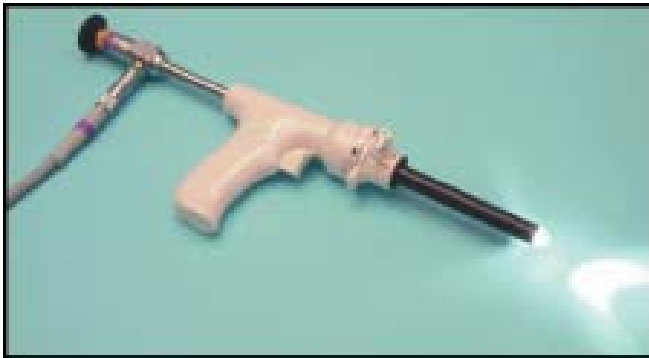

Fig. 5.51: Optical trocar

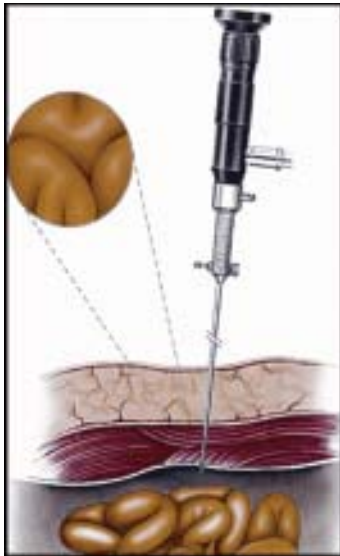


Fig. 5.52: Optical needle

Some Veress needle with inbuilt fiberoptic telescope is also used for direct visualization at the time of its introduction but quality of picture is not optimum for very safe access.

#### *Postoperative Chest and Shoulder Pain After Laparoscopy*

Residual CO<sub>2</sub> left inside the abdominal cavity sometime cause considerable discomfort like chest pain and shoulder tip pain. The cause of this discomfort is that residual CO<sub>2</sub> gets trapped in the subdiaphragmatic recesses and then irritate diaphragm. Irritation of diaphragm causes referred pain in chest and over shoulder tip. This pain is more when patient sits upright. To avoid this entrapment of CO<sub>2</sub> it is good practice to put the patient in the Trendelenburg's position at the time of removing gas at the end of surgery. Only after

removing the last telescopic cannula the Trendelenburg's position of the patient is discontinued.

Some surgeon leave some fluid like ringer lactate inside the abdominal cavity to divert gas away from sub diaphragmatic space but effect of this is controversial.

Subdiaphragmatic gas which remains inside is absorbed completely within 24 to 48 hours after surgery.

#### Complications of Access Technique

Improper trocar insertion causes most of the operative complications of laparoscopic surgery. Examples are injury to the bowel, major Vessels, bladder, inferior epigastric vessels and subcutaneous emphysema. Other complications include thermal injury to the bowel, abdominal wall contusions, trocar-site herniation with possible bowel obstruction, and trocar-site tumor implants. However, the overall incidence of complications is relatively low (about 2%).

#### Visceral Injuries

##### *Incidence of Injury of Hollow Viscus*

- Small bowel (2.7%)
- Large bowel (0.15%)
- Bladder (0.5%)
- Stomach (0.02%).

##### *Solid organs*

- Liver
- Spleen.

##### *Vessel injury*

- Inferior epigastric
- Omental
- Mesenteric vessels
- Aorta
- Inferior vena cava.

##### *Other Complications*

- Gas embolism (1:10 000 to 1:60 000, but lethal)
- Pneumo-omentum
- Surgical emphysema



Fig. 5.53: Laparolift

- Pneumomediastinum
- Sudden collapse.

The anesthetist should check for conditions such as drug reactions pneumothorax, gas embolism which may give rise to myocardial arrhythmias.

If Cardiac Arrhythmia is found:

- Stop insufflation
- Withdraw instrument and remove CO<sub>2</sub> by opening the valve but leave port in position.
- Turn the patient to left
- Correct hypoxia and resuscitate
- Postpone surgery.

If case of severe hypotension, proceed to immediate laparotomy with all instruments left *in situ*. Assume retroperitoneal bleeding to be the cause.

### Mild to Moderate Hypotension

In cases of moderate hypotension the surgeon should consider discontinuing gas insufflation immediately and reducing intra-abdominal pressure to 8.0 mm Hg. 360° scan of the abdominal cavity should be performed immediately to rule out retroperitoneal bleeding.

If bleeding or expanding hematoma is seen, one should proceed immediately to long midline laparotomy and compression of the bleeding vessel. Blood should be aspirated, bleeder is exposed and bleeding should be controlled with vascular clamps. When necessary, operator should obtain assistance of a vascular surgeon.



Fig. 5.54: Laparofan attached with laparolift after introduction inside abdominal cavity

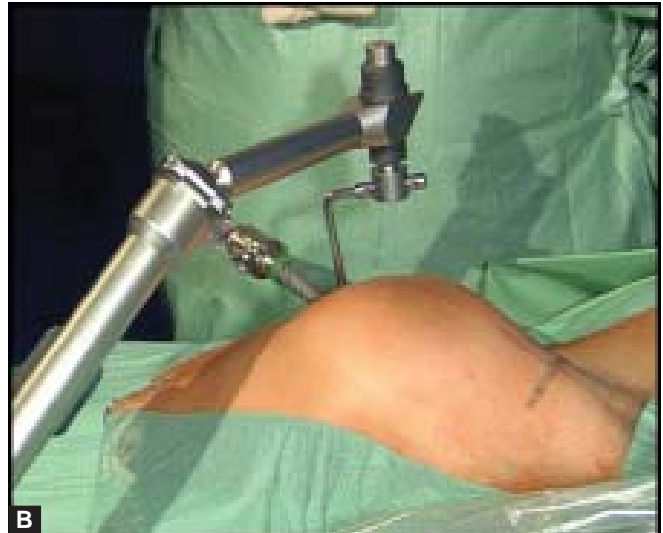
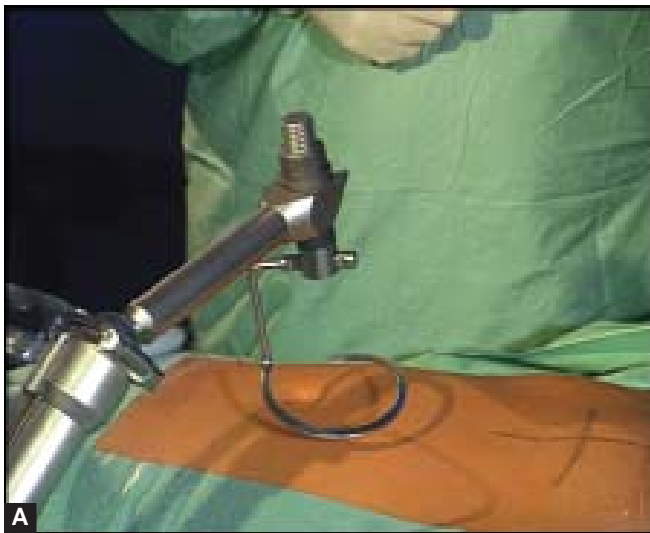

Fig. 5.55: Abdolift (another variety of abdominal lifting device)

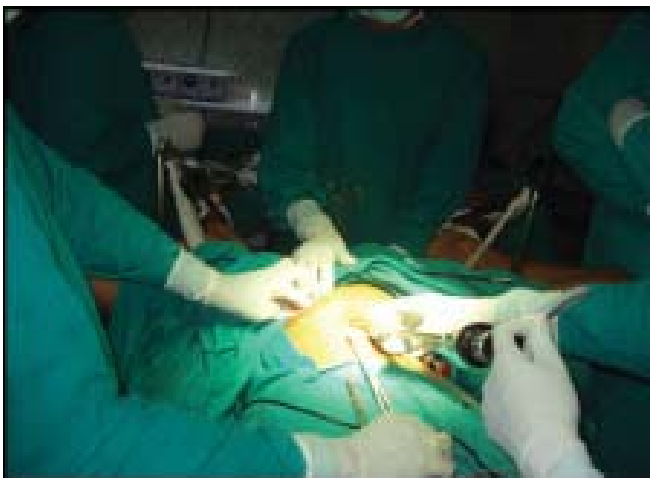### Withdrawal of Instrument and Ports

Once the surgery is finished all the instrument should be removed carefully under vision. All the accessory port should be removed and the gas is removed by releasing the valve of 10 mm cannulas. The primary port should be taken out in the end (Fig. 5.57).

If last port is suddenly withdrawn sudden suction effect of cannula can pull the omentum or bowel inside the port wound, the chances of port site hernia and adhesion is much higher in this case. It is a good practice to insert some blunt instrument or telescope



**Figs 5.56A and B:** Abdolift lifting the abdominal cavity

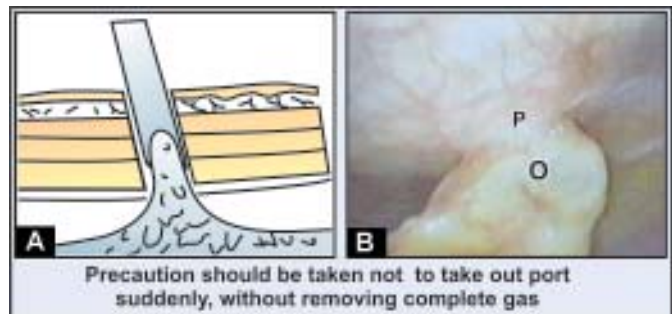


**Fig. 5.57:** The tip of telescope should be introduced in and cannula is pulled over telescope to prevent suction of omentum or bowel

inside the abdomen while removing the last cannula out over that instrument, to prevent inadvertent entrapment of omentum or bowel (Figs 5.58A and B).

### PORT CLOSURE TECHNIQUES

The access technique will result in breach in continuity of abdominal wall which need to be repaired at the end of surgery. All the 10 mm or greater than 10 mm port should be repaired properly to prevent any future possibility of hernia. The rectus sheath is only necessary



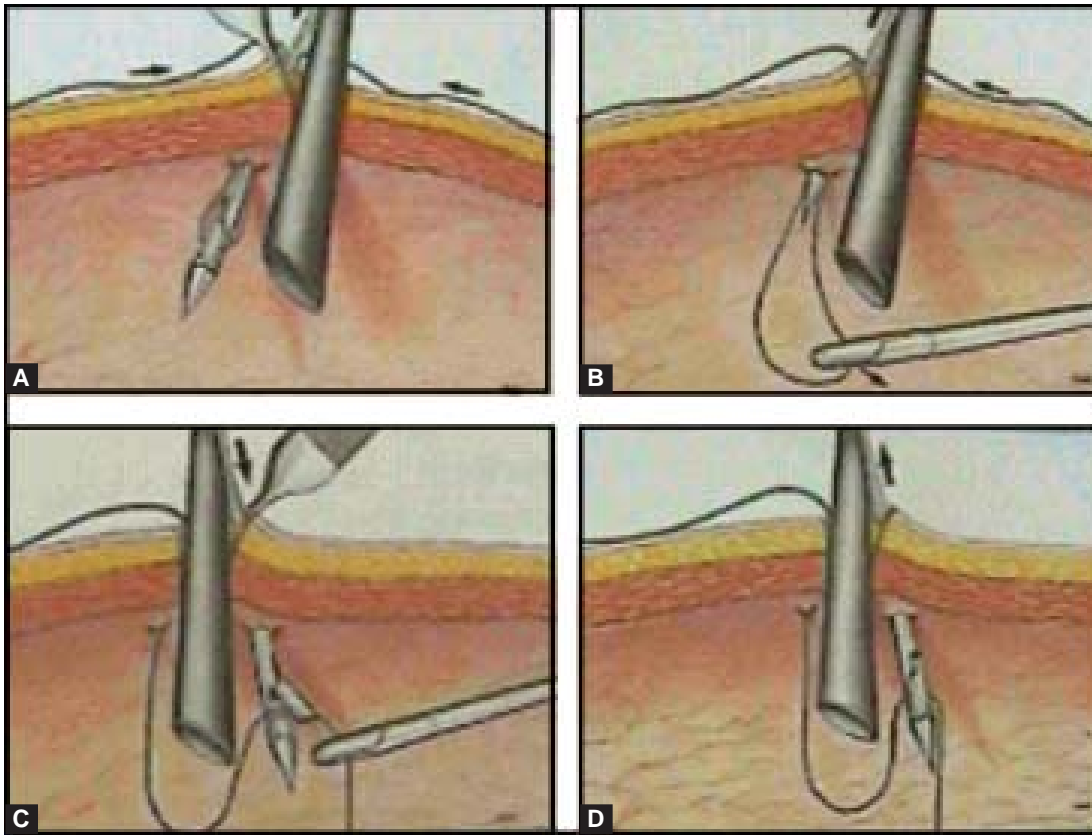
**Figs 5.58A and B:** Adhesion may form if cannula is pulled rapidly at the end of surgery  
P: Peritoneum, O: Omentum

to suture with Vicryl. Only one stitch is required in middle which will convert 10 mm wound into 5 mm. The 5 mm port wounds are not necessary to repair (Figs 5.59A to D).

Various types of port closure instruments are available. The suture passer is a convenient instrument for port closure it is used to pass the thread on the side of cannula and then it is tied externally (Figs 5.60A and B).

For port closure specially designed port closure instruments are also available commercially, like port closure needle and aneurism needle.


After closing the rectus sheath the skin can be closed by intradermal, skin stapler or by any of the surgical skin glues available (Fig. 5.61).



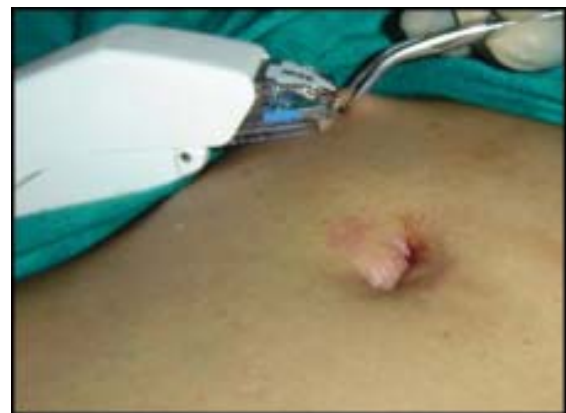**Figs 5.59A to D:** Port closure with the help of suture passer

### Gasless Laparoscopic Surgery

Conventional laparoscopic surgery requires pneumoperitoneum to elevate the abdominal wall for proper exposure. A continuous insufflation of a non-combustible gas in a sealed environment is essential part of minimal access surgery. Many undesirable physiological side effects have been observed with CO<sub>2</sub> pneumoperitoneum. Furthermore, it has been necessary to retrain surgeons to use specialized instruments in order to operate on video images. Abdominal lifting mechanical devices can provide working space without pneumoperitoneum. With gasless technique, conventional instruments can be used, direct visualization of abdominal viscera is possible, and digital examination of abdominal contents can be performed without the fear of losing exposure. Since these procedures are being performed in an isobaric abdominal cavity, the risk of body fluid contamination to operating team is diminished when compared to open or traditional laparoscopic surgery. Gasless laparoscopic surgery is primarily advocated for the patients who are at high-risk of pneumoperitoneum.



**Figs 5.60A and B:** Port closure needle and aneurysm needle



**Fig. 5.61:** Closure of skin wound by skin stapler

A variety of abdominal lift devices have been developed recently to provide working space. Although gasless laparoscopic surgery is good for patient with high-risk of pneumoperitoneum, due to intraoperative problems and complications and because of sub-optimal exposure, gasless laparoscopic surgery is still not considered as the prime modality for every patient.

All the gasless systems can be used on their own or with low pressure insufflation (4-6 mm Hg).

#### *There are Three Basic Types*

1. Rubber tube sling abdominal wall lifts.
2. Planar intraperitoneal abdominal wall retraction lift devices.
3. Subcutaneous abdominal wall lift devices.

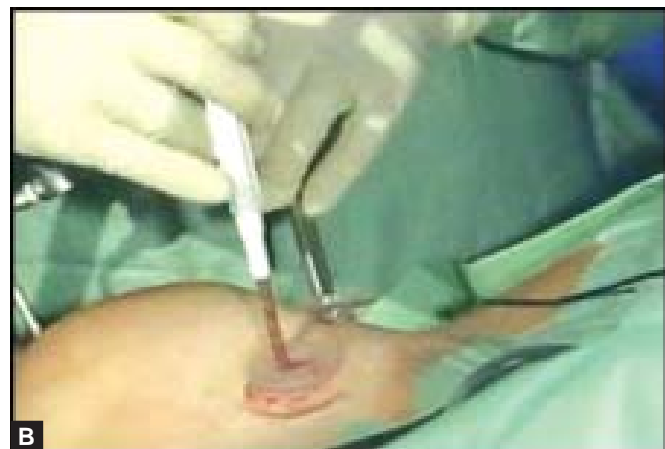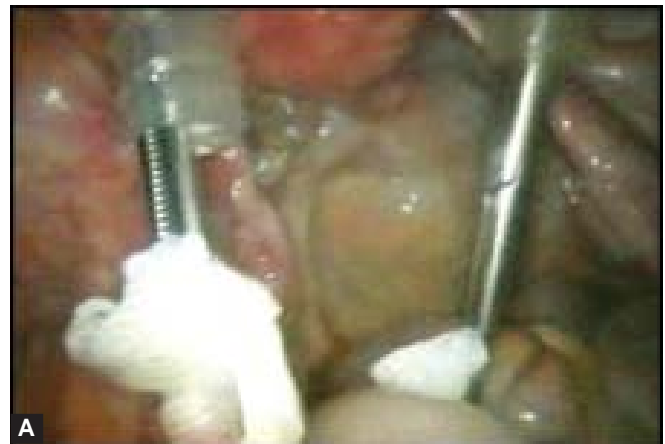None of these techniques gives as good a laparoscopic exposure as the pressurised pneumoperitoneum because they produce a tent-like elevation of the abdominal wall rather than an elevated expansion and they do not depress the hollow organs and omentum. Exposure is improved when low pressure insufflation is added (Table 5.1).

Several devices for gasless laparoscopy have been developed recently. The Laparolift (Origin Med systems) is commercially available device routinely used by many surgeons and gynaecologist worldwide (Figs 5.53 to 5.55).

It consists of an adjustable arm that is attached to the side of the operating table and sterilely draped (Fig. 5.56A and B). The surgeon can raise and lower it electronically. The arm is connected to the Laparofan, a disposable sterile device with two metal blades (available in 10 and 15 cm lengths) that are inserted through the umbilical incision in an overlapped position. After entering the peritoneal space, the

Laparofan paddles are spread. Using the dovetail connector, the Laparofan retractor is attached to the Laparolift arm and raised, creating a working cavity for laparoscopic surgery. It is intended to be used as a substitute for, or in conjunction with, pneumoperitoneum for abdominal wall retraction. The blades are then splayed out and locked into a V by tabs on the plastic handle, which is fixed to the end of the adjustable arm. The maximum lifting force of 13.6 kg is equivalent to a pneumoperitoneum pressure of 15 mm Hg. The laparoscope is inserted through the same incision, cephalad to the Laparofan.

The physiologic changes associated with CO<sub>2</sub> pneumoperitoneum are well tolerated in healthy patients but may result in life-threatening cardiac arrhythmia, myocardial infarction, cardiac failure, or pulmonary insufficiency in compromised patients who cannot compensate for these alterations in

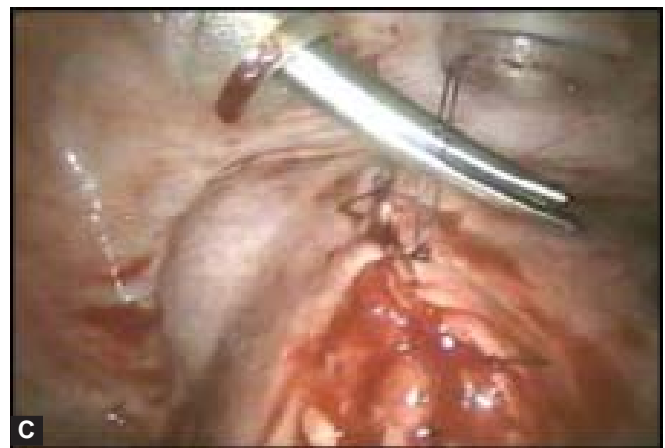
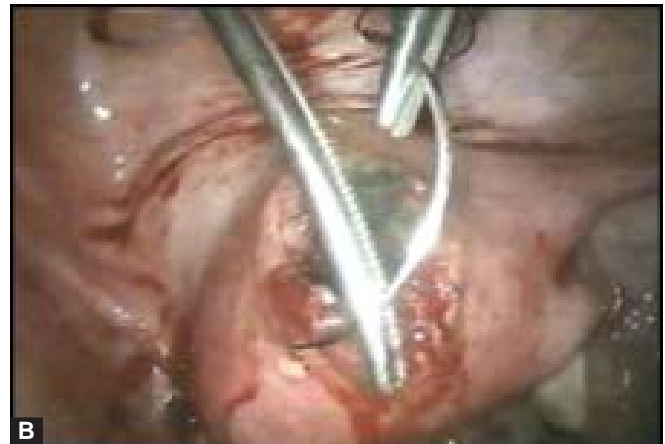
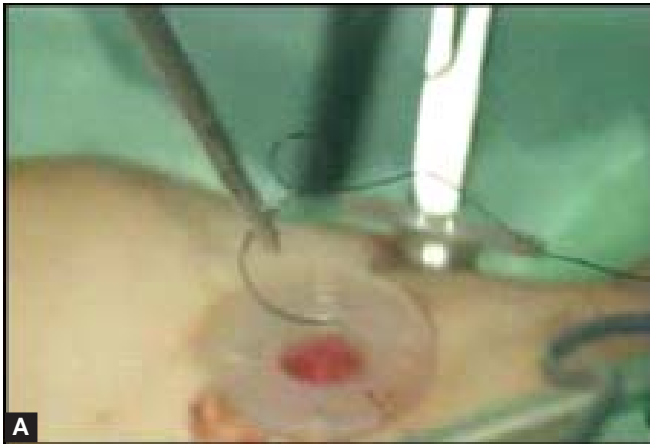**Figs 5.62A and B:** Use of open surgical instrument in gasless laparoscopic surgery



**Table 5.1: Problems due to pneumoperitoneum**

Hypothermia
Cardiac arrhythmia
Cardiovascular collapse
Pulmonary insufficiency
Gas embolism
Venous thrombosis
Cerebral edema/ischemia
Ocular hypertension
Extraperitoneal insufflation(subcutaneous emphysema, pneumomediastinum)



hemodynamic. A gasless laparoscopic approach could provide an added margin of safety for these patients. Patients undergoing laparoscopic surgery for malignancy or laparoscopically assisted vaginal hysterectomy may also benefit from gasless laparoscopy. Another potential advantage of gasless laparoscopy is the ability to use continuous suction and conventional laparotomy instruments (Figs 5.62A to 5.62C).

## Section One

### *Disadvantages of Gasless Laparoscopic Surgery*

- Marked guttering effect of lateral abdominal wall result after lifting anterior abdominal wall.
- Anterior abdominal adhesion can make insertion of these mechanical device difficult and visualization almost impossible.
- It is a space occupying as instrument takes all the ergonomically good space of port position.
- It only elevates anterior abdominal wall whereas gas creates workable space in whole abdominal cavity.
- Sometime causes pressure necrosis of superior or inferior epigastric vessels.
- Bigger incision is required in the umbilicus.
- Difficult to perform in presence of ileus.
- Difficult peritoneal toileting at remote places.

Studies to date have demonstrated that surgical procedures with gasless laparoscopy are technically more difficult than those performed with adequate pneumoperitoneum owing to impaired visualization

**Figs 5.63A to C:** Use of open needle holder and suturing technique in gasless laparoscopic

from bowel in the pelvis. As with any new laparoscopic device, the initial enthusiasm over gasless laparoscopy has been tempered by actual clinical experience. However, because gasless laparoscopy still promises significant advantages over CO<sub>2</sub> pneumoperitoneum in high-risk patient, it is anticipated that interest in this technique will continue with improvements that will eliminate the current limitations to its use.

### **BIBLIOGRAPHY**

1. Bahm B, Kuigge M, Kroft M, Grundel K, Boerick U. Influence of different trocar tips on abdominal wall penetration during laparoscopy. *Surg Endosc* 1998;12:1434-8.
2. Moberg AC, Montgomery A. *Surg Endosc* 2005;19(9): 1196-9.
3. Zucker KA. *Surgical Laparoscopy*. 2001; 29-39.